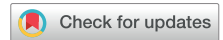

Featured Review Article

Stability of Class II corrections with removable and fixed functional appliances: A literature review



Alexandre Moro^{a,b,*}, Camila F.P. Mattos^c, Suelen W. Borges^d, Carlos Flores-Mir^e, Francielle Topolski^a

^a Professor, School of Health Sciences, Universidade Positivo, Curitiba, Paraná, Brazil

^b Professor, Department of Orthodontics, Universidade Federal do Paraná, Curitiba, Paraná, Brazil

^c Student, MSc Program in Dentistry, School of Health Sciences, Universidade Positivo, Curitiba, Paraná, Brazil

^d Student, PhD Program in Dentistry, School of Health Sciences, Universidade Positivo, Curitiba, Paraná, Brazil

^e Professor, School of Dentistry, Faculty of Medicine and Dentistry, University of Alberta, Edmonton, Alberta, Canada

ARTICLE INFO

Article history:

Received 11 February 2020

Received in revised form

24 April 2020

Accepted 27 April 2020

Available online 27 May 2020

Keywords:

Class II malocclusion

Fixed retainer

Functional appliance

Relapse

ABSTRACT

Background: Class II functional appliances have been used in orthodontics for over 100 years. Although the stability of corrections is one of the main goals of orthodontic treatment, there is a paucity of longitudinal studies on the long-term stability of treatment of Class II malocclusion based on functional appliances.

Methods: This narrative review attempts to summarize the limited related evidence available and discusses the clinical implications of important aspects related to occlusal and skeletal changes that arise after Class II malocclusion treatment with functional appliances.

Results: The occlusal changes obtained through Class II functional treatment do mostly exhibit long-term stability. While mild posttreatment changes occurred, they were most likely due to physiologic aging processes and not likely associated with actual treatment relapse. Long-term retention in the lower jaw would be particularly beneficial. A stable occlusion with good intercuspation in the posterior arches seems more likely to preserve a Class I occlusion after treatment through dentoalveolar compensatory mechanisms. After treatment, the maxilla and the mandible do grow anteriorly, with the mandible growing more than the maxilla. Patients treated with functional appliances are not likely to develop TMJ disorders over the long term.

Conclusions: Long term skeletal corrections achieved with functional appliances seem to be overall stable. Class II molar and overjet relapses can be likely explained by a combination of tooth movement and an unfavorable posttreatment maxillomandibular growth pattern, especially when combined with unstable interdigitation of the posterior teeth. No specific intermaxillary retention approach has been assessed yet.

© 2020 World Federation of Orthodontists.

1. Introduction

Orthodontic treatment has multiple goals, but stability of corrections is a major goal. Relapse after treatment has been a long-established concern in orthodontics. In 1907, Angle [1] mentioned

that the teeth do not remain in their new positions if treatment fails to achieve normal occlusion.

More often than not, orthodontic treatments are long and complex. Even though orthodontics consistently produces astonishing outcomes, these outcomes may be negatively affected after removal of the active appliances. The usual type of orthodontic relapse is well documented in the literature [2], and includes crowding or diastemas, recurrence of previous overjet and overbite, and unstable Class II and Class III molar relationship corrections.

Although several factors may affect the outcomes of orthodontic treatment in the long run, the outcomes are likely to be unstable, because of three major reasons [3]: 1) periodontal tissues are affected by orthodontic tooth movements and take time to adjust after removal of the appliances; 2) soft tissues (lips, cheeks, tongue) exert constant pressure on the teeth until an equilibrium is attained; as described by Rogers [4] in 1922, muscle forces should

Funding: The authors have not declared a specific grant for this research from any funding agency in the public, commercial, or not-for-profit sectors.

Competing interest: Authors have completed and submitted the ICMJE Form for Disclosure of potential conflicts of interest. None reported.

Patient/Parent consent: Consent obtained from all the four patients in this article.

Provenance and peer review: Not commissioned; Externally peer reviewed.

* Corresponding author: School of Health Sciences, Universidade Positivo, Rua Professor Pedro Viriato Parigot de Souza, 5300, 81280-330, Curitiba - PR, Brazil.

E-mail address: alexandremoro@uol.com.br (A. Moro).

Table 1
Longitudinal studies on the stability of treatment with removable functional appliances

Author, year	Method	Participants and intervention	Outcomes	Conclusions
DeVincenzo 1991 [17]	Recruitment period: 1982 to 1984 Trial design: Retrospective Measurement methods: Cephalometric analysis.	Forty-seven girls with Class II malocclusion treated with an Activator were assessed. After functional appliance treatment, which was over when a Class I molar relationship was attained, all patients underwent fixed appliance treatment (29 cases treated with extraction and 18 with nonextraction). In the control group, 47 girls (55% Class I and 45% Class II) were selected and matched with their treated peers.	In the postfunctional phases, mandibular length (ML) did not increase as much as in the control group. After 4 years, there was no additional increase in long-term ML, when compared with the control group. Had the treatment duration been 2 years, the increase in length would have been highly significant; and had the treatment lasted 3 years, ML would have been smaller but significant. Impressive outcomes disappeared by the end of 4 years. The same was observed when 20 patients were compared with a control group with Class II malocclusion	It was concluded that, when a functional appliance is used and negligible orthopedic response is achieved, there will be little or no relapse in postfunctional assessments. Conversely, the better the orthopedic outcome, the greater the possibility of relapse.
Ferrazini 2008 [18]	Recruitment period: patients were invited for a check-up visit in 2005. Trial design: Retrospective. Measurement methods: Cephalometric analysis and a questionnaire.	Treatment with a removable appliance acting as an activator was evaluated in a group of 18 Class II/2 patients (Group I) 3 times: before treatment (T0, 10.8 years); removal of all orthodontic appliances (T1, 14.5 years); and at least 20 years later (T20, 36.1 years). The remaining 26 treated patients (Group II), were evaluated only at initial and final treatment (at T0, 10.1 years, and T1, 14.2 years).	Treatment corrected Class II/2, normalizing the ANB angle, the Wits appraisal, the inclination of the upper incisors, and intercuspation. The PAR-index, was 14.3 and was reduced by the treatment to 3.65. Twenty years later, this value changed to 6.72. Palatal-mandibular plane angle worsened slightly, whereas the inclination of the lower incisors was practically unchanged. Only minor changes had occurred, except for a nearly 5° relapse of the upper incisor inclination, maintaining a gain of only 1.5°.	The one-stage early treatment with removable appliances of the Class II/2 analyzed in this study has been shown to be simple, efficient, and less a burden to the patients, with good stability for more than 20 years. The stability could certainly be improved with a long-term fixed retention in the lower anterior arch.
Freeman et al. 2009 [19]	Recruitment period: Not reported Trial design: Retrospective Measurement methods: Cephalometric analysis.	The sample consisted of 30 patients (17 boys, 13 girls) treated exclusively with FR-2. The mean age at the start of treatment was 8 years (T1), with a posttreatment cephalogram (T2) taken 10 years later. The control group included 20 subjects (11 boys, 9 girls) with untreated Class II. FR-2—treated subjects were followed for an average of 6 years and 9 months beyond the active phase of appliance therapy and for at least 3 years after the end of the retention periods, for an average overall observation of 9 years and 11 months.	The FR-2 group maintained stable correction of the initial Class II malocclusion over the evaluation period. Significant mandibular and intermaxillary changes and dentoalveolar changes were noted in the treated group, with a 3-mm long-term increase in mandibular length compared with the untreated Class II controls.	The FR-2 appliance, over a long period, has a minor restraining effect on the position of the maxilla (1.5 mm) and a significant enhancing effect on mandibular length and sagittal position. FR-2 has its greatest long-term effects on anteroposterior intermaxillary measurements.
Angelieri et al. 2014 [20]	Recruitment period: Not reported Trial design: Prospective Measurement methods: Cephalometric analysis.	The FR-2 sample comprised 17 subjects (10 boys and 7 girls, mean age of 10.8 years) who were treated with the FR-2 appliance for 1.7 years and reevaluated 7.1 years after treatment. The control group consisted of 17 class II subjects (9 boys and 8 girls, mean age of 11.3 years), matched to the treated group.	FR-2 treatment provided a significant improvement in the maxillomandibular relationship due to an increase in mandibular length (3.7 mm, T1-T3) compared with controls, which remained stable over time. Also, overjet, overbite, and molar relationship corrections demonstrated stability. Among dentoalveolar changes, only the increased mesial movement of the mandibular molars in the FR-2 group demonstrated stability.	Correction of Class II malocclusion remained stable 7 years after FR-2 treatment mainly due to the stability of the skeletal changes.

(Continued on next page)

Table 1 (Continued)

Author, year	Method	Participants and intervention	Outcomes	Conclusions
Malta et al. 2010 [21]	Recruitment period: Not reported Trial design: Retrospective Measurement methods: Cephalometric analysis.	Treatment with Bionator, followed by approximately 1 year of fixed appliance therapy. The treatment sample consisted of 20 Class II patients (6 males and 14 females). Mean age at the start of treatment was 10 years and 2 months (T1); at posttreatment, 12 years and 4 months (T2); and at long-term follow-up, 18 years and 11 months. The control group consisted of 20 subjects (8 males and 12 females) with untreated Class II.	The Bionator group showed significant and favorable T1–T2 changes both at the skeletal and dentoalveolar levels. The treated group showed a final improvement in soft tissue pogonion of approximately 2.5 mm. Significant mandibular changes were noted in the treated group, with a net average of 3.3-mm long-term increase in mandibular length compared with untreated Class II controls.	Bionator appliance produced a significant enhancing effect on mandibular length, significantly improved overjet and the molar relationship, with a significant reduction of overbite associated with an increase in lower anterior facial height.
Pavoni et al. 2018 [22]	Recruitment period: Not reported Trial design: Retrospective Measurement methods: Cephalometric analysis.	A group of 46 patients (23 females and 23 males) with Class II treated consecutively with either Bionator or Activator, followed by fixed appliances. The treated sample was evaluated at T1, start of treatment (mean age: 9.9 years); T2, end of functional treatment and before fixed appliances (mean age: 11.9 years); and T3, long-term observation (mean age: 18.3 years). Comparison was made with a matched control group of 31 subjects (16 females and 15 males) with untreated Class II.	When treatment was initiated before puberty, Class II correction was mostly confined to dentoalveolar changes, with significant improvements of both overjet and molar relationships. On the other hand, treatment initiated at puberty produced significant long-term increase in total mandibular length (Co –Gn + 5.5 mm), a significant chin advancement (Pg to N perp + 3.1 mm), and a significant reduction in the Wits appraisal of –5.8 mm was observed. Lower intercanine distance remained fairly unchanged during treatment, but decreased significantly during follow-up. Lower incisor irregularity improved slightly during treatment but increased significantly in the long term (from 2.0 to 3.7 mm). After treatment, sagittal molar relationships on both sides were improved and overjet and overbite reduced; these significant changes remained stable in the long term. The PAR index was significantly lower after treatment, (T0–T1, 18–6.5) showing nonsignificant increase during follow-up (T2 = 12).	Treatment with removable functional appliances at puberty induced a significant long-term enhancement of mandibular growth with an increase in mandibular ramus height and protrusion of the chin. Prepubertal Class II treatment results primarily in dentoalveolar changes.
Jungbauer et al. 2019 [23]	Recruitment period: Bionator cases collected in 2018. Treatment was initiated between 1973 and 1979 Trial design: Retrospective Measurement methods: Dental cast analysis.	Evaluation of 18 patients with skeletal Class II treated with a Bionator without any additional fixed therapy was performed at three stages: before (T0), after (T1), and 20 years after (T2) treatment. Mean patient age was 9.8 years before treatment (T0), 13.3 years after Bionator treatment (T1), and 33.3 years after 20 years of follow-up (T2).	Lower intercanine distance remained fairly unchanged during treatment, but decreased significantly during follow-up. Lower incisor irregularity improved slightly during treatment but increased significantly in the long term (from 2.0 to 3.7 mm). After treatment, sagittal molar relationships on both sides were improved and overjet and overbite reduced; these significant changes remained stable in the long term. The PAR index was significantly lower after treatment, (T0–T1, 18–6.5) showing nonsignificant increase during follow-up (T2 = 12).	The improved sagittal relationship and the reduced overjet and PAR index remained fairly stable. Long-term changes were most likely due to physiological aging processes and are not associated with Bionator treatment.
Keski-Nisula et al. 2019 [24]	Recruitment period: Children who were born 1992/3. Trial design: Prospective cohort study Measurement methods: Cephalometric and dental analyses	Sixty-five Class II patients (38 females and 27 males), treated with an eruption guidance appliance (EGA) in early mixed dentition, were compared with 58 children (26 females and 32 males) with untreated Class II. The early treatment was carried out with EGA from T1 to T2, followed by retention. Retention was maintained using an EGA. The mean age in the treatment group at the start (T1) and end of treatment (T2) was 5.4 years and 8.5 years, respectively, and 16.7 years at the final examination (T3). In the control group, the mean age at T1 and T2 were 5.1 years and 8.4 years, respectively.	The mean overjet of the treatment and control groups at T1 was 3.4 mm. At the end of T2, it was 2.2 mm for the treatment and 4.7 mm for the control. At T3, the overjet for the treatment group was 2.1 mm. In the treatment group, the frequency of Class II decreased from 100% to 14% during the treatment. At T2, the treatment and control groups showed statistically significant differences in all occlusal variables. In the treated children, mandibular length increased 5 mm more from T1 to T2 compared with the control children.	A clinically significant correction of the molar relationship, overjet, overbite, incisor alignment, and growth enhancement of the mandible were observed after treatment in early mixed dentition. The treatment results remained largely stable in the early permanent dentition. However, an increase was observed in overbite and lower crowding. None of the children treated in early mixed dentition needed a second treatment phase.

Cacciatore et al. 2019 [16]	<p>Recruitment period: Unrestricted electronic search of 24 databases and additional manual searches up to March 2018.</p> <p>Trial design: A systematic review and meta-analysis</p> <p>Measurement methods: Cephalometric analysis.</p>	<p>Inclusion criteria: Randomized and nonrandomized controlled trials reporting on cephalometric skeletal and soft tissue measurements of Class II patients (aged 16 years or younger) treated with functional appliances, worn alone or in combination with multibracket therapy, compared with untreated Class II subjects.</p> <p>The whole observational periods of included trials ranged from 4.7 to 10.2 years.</p>	<p>Eight nonrandomized studies published in 12 papers were included. Functional appliances produced a significant improvement of the maxillomandibular relationship, at almost all time points (Wits appraisal at the end of growth, mean difference (MD) –3.52 mm). The greatest increase in mandibular length was recorded in patients aged 18 years and older (Co-Gn, MD 3.20 mm), although the improvement of the mandibular projection was negligible or not significant.</p> <p>Mean overjet reduction of 6.22 mm arose during treatment, with canine and molar relationship improvements of 3.34 mm and 2.67 mm, respectively. In the 12 months posttreatment, a relapse of 0.67 mm and 0.06 mm in overjet and molar relationship, respectively, was observed, with 25% of subjects having overjet relapse of >1 mm. There is weak evidence that the treatment-induced change in overjet is linked to overjet relapse.</p>	<p>Functional appliances may be effective in correcting skeletal Class II malocclusion in the long term; however, the quality of evidence was very low and clinical significance was limited.</p>
Oliver et al. 2020 [25]	<p>Recruitment period: Not reported</p> <p>Trial design: Prospective evaluation</p> <p>Measurement methods: Dental casts and cephalometric analysis.</p>	<p>Sixty-four participants (34 boys; 30 girls) seen for posttreatment review at a 12-month follow-up. The mean age at beginning of twin lock therapy was 12.5 years.</p> <p>The mean age at debonding was 15.8 years.</p> <p>The mean age at posttreatment review was 16.8 years.</p> <p>There was no control group.</p> <p>63% of the participants (n = 41) were treated on a nonextraction basis. The fixed appliance phase lasted 1.88 years on average, resulting in a total treatment time of 3.26 years.</p> <p>All participants received some form of retainer.</p>	<p>Mean overjet reduction of 6.22 mm arose during treatment, with canine and molar relationship improvements of 3.34 mm and 2.67 mm, respectively. In the 12 months posttreatment, a relapse of 0.67 mm and 0.06 mm in overjet and molar relationship, respectively, was observed, with 25% of subjects having overjet relapse of >1 mm. There is weak evidence that the treatment-induced change in overjet is linked to overjet relapse.</p>	<p>Overall, acceptable levels of stability were observed, although appreciable relapse was noted in 25% of participants. Neither the degree of buccal segment interdigitation nor pretreatment skeletal discrepancy was predictive of anteroposterior occlusal stability.</p>

ANB, angle formed by the intersection of lines from points A and B to point N (Nasion); Gn (Gnathion), the most anterior inferior point on the bony chin; ML, mandibular length; Pg (Pogonion), the most anterior point on the bony chin; Co (Condylion), the most posterosuperior point of the condylar outline; EGA, eruption guidance appliance (Nite-Guide or Occlus-o-Guide; Ortho-Tain, Winnetka, IL); MD, mean difference; PAR, peer assessment rating.

Table 2

Longitudinal studies on the stability of treatment with fixed functional appliances

Author, year	Method	Participants and intervention	Outcomes	Conclusions
Pancherz et al. 2014 [26]	Recruitment period: 22 patients with Class II Div1 treated with the Herbst appliance in 1977 and 1978. In 2011 and 2012, they were recalled. Trial design: Retrospective. Measurement methods: Dental cast analysis.	The first 14 (12 men, 2 women) patients from a sample of 22. Mean age (y): T1: 12.5; T2: 14.3; T3: 20.4; T4: 46.1. The subjects were reexamined after therapy at the ages of 20 years and 46 years. Examinations were analyzed before (T1) and after (T2) treatment, and at 6 years (T3) and 32 years (T4) after treatment.	Minor changes in maxillary and mandibular dental arch perimeters and arch widths were seen during posttreatment (T2–T4). Mandibular incisor irregularity increased continuously during the 32-year follow-up period. Class II molar and canine relationships had a minor relapse during the early posttreatment period (T2–T3); during the late posttreatment period (T3–T4), molar and canine relationships remained, on average, unchanged. After treatment (T2–T4), overjet remained, on average, unchanged, but overbite increased nonsignificantly.	A Class II relapse seemed to be caused by unstable interdigitation of the occluding teeth, a persistent oral habit, or an insufficient retention regimen after treatment. Most posttreatment changes occurred within the first years after treatment. After the age of 20 years, only minor changes were noted. Long-term posttreatment changes in maxillary and mandibular dental arch perimeters and widths as well as in mandibular incisor irregularity seemed to occur independently of treatment and as a result of physiologic dentoalveolar change throughout adulthood.
Pancherz et al. 2014 [27]	Recruitment period: 22 patients with Class II Division 1 treated with the Herbst appliance in 1977 and 1978. In 2011 and 2012, they were recalled. Trial design: Retrospective. Measurement methods: Intraoral photographs, mandibular dental casts, and lateral head films.	The first 14 (12 men, 2 women) patients from a sample of 22 with Class II Division 1 malocclusions consecutively treated with the banded Herbst appliance. Mean age (y): T1: 12.5; T2: 14.3; T3: 20.4; T4: 46.1. The subjects were reexamined after therapy at the ages of 20 years and 46 years. Examinations were analyzed before (T1) and after (T2) treatment, and at 6 years (T3) and 32 years (T4) after treatment.	From T1 to T2, the incisors were proclined in 11 (79%) of the 14 patients, with an average value of 5.2°. From T2 to T4, tooth inclination recovered completely in seven (63%) of the 11 patients. Incisor irregularity values were, on average, 3.4 mm at T1 and 3.0 mm at T2. They increased by 40% from T2 to T4 and had an average value of 5.0 mm at T4.	In Herbst patients followed for 32 years after therapy, proclined mandibular incisors generally relapsed. The increase in posttreatment incisor tooth irregularity was not thought to be related to incisor tooth inclination changes but more likely resulted from physiologic processes occurring throughout life. Minor gingival recessions seen in a few patients 32 years after treatment did not seem to be related to the posttreatment tooth inclination changes.
Pancherz et al. 2015 [28]	Recruitment period: 22 patients with Class II:1 treated with the Herbst appliance in 1977 and 1978. In 2011 and 2012, they were recalled. Trial design: Retrospective. Measurement methods: Lateral head films.	The first 14 (12 men, 2 women) patients from a sample of 22 with Class II Division 1 malocclusions consecutively treated with the banded Herbst appliance. Mean age (y): T1: 12.5; T2: 14.3; T3: 20.4; T4: 46.1. The subjects were reexamined after therapy at the ages of 20 years and 46 years. Examinations were analyzed before (T1) and after (T2) treatment, and at 6 years (T3) and 32 years (T4) after treatment.	The following significant skeletal changes occurred from T2 to T3: increase of the SNB (1.0°), decrease of the ANB (0.9°), and decrease of the ML/NSL (2.5°). No significant angular changes occurred from T3 to T4. In the analysis of sagittal changes from T2 to T3, the mandible (6.1 mm) and the maxilla (3.0 mm) grew forward. From T3 to T4, the mandible (2.8 mm) and the maxilla (3.1 mm) continued to grow forward. Thus, there was continuous forward growth of the mandible (8.9 mm) and of the maxilla (6.1 mm) throughout the posttreatment (T2–T4) period.	In all subjects, there were large amounts of sagittal and vertical growth after the age of 20 years. However, the question of when growth stopped between the ages of 20 and 46 years remains unanswered. Closure of the radius epiphyseal/diaphyseal plate is not a useful indicator of full skeletal growth. Posttreatment Class II relapse seemed to be due to an unfavorable maxillomandibular growth pattern, with insufficient dentoalveolar compensation, especially when combined with unstable interdigitation of the teeth.
Pancherz et al. 2015 [29]	Recruitment period: 22 patients with Class II Division 1 treated with the Herbst appliance in 1977 and 1978. In 2011 and 2012, they were recalled. Trial design: Retrospective. Measurement methods: TMJ radiography, clinical examination, and questionnaire.	The first 14 (12 men, 2 women) patients from a sample of 22 with Class II Division 1 malocclusions consecutively treated with the banded Herbst appliance. Mean age (y): T1: 12.5; T2: 14.3; T3: 20.4; T4: 46.1. The subjects were re-examined after therapy at the ages of 20 years and 46 years. Examinations were analyzed before (T1) and after (T2) treatment, and at 6 years (T3) and 32 years (T4) after treatment.	There were signs of osteoarthritis in one patient 6 years after Herbst therapy. At the 32-year follow-up, two additional patients had developed signs of osteoarthritis. At the 6-year follow-up, TMJ clicking was present in two patients, although none of them reported TMJ pain. At the 32-year follow-up, six patients had TMJ clicking and one patient had TMJ pain.	Their very long term follow-up study after Herbst therapy revealed only minor TMJ disorders. TMJ findings 6 years and 32 years after Herbst treatment corresponded to those observed in the general population. Thus, in the very long term, the Herbst appliance does not appear to be harmful to the TMJ.

Bock et al. 2016 [30]	Recruitment period: Systematic electronic search strategy conducted in two main databases for literature published until December 2013. Trial design: Systematic review and meta-analysis. Measurement methods: Dental cast and cephalometric analyses.	Inclusion criteria: the articles had to contain clear data on the following: Class II malocclusion with a fixed functional appliance (>5 patients), posttreatment period ≥ 1 year, assessment of ANB angle, Wits appraisal, molar relationship, soft tissue profile convexity excluding the nose, and overjet and/or overbite. The literature search revealed 20 scientific publications.	The mean values for post-Tx relapse (percentages relative to the Tx changes) were as follows: ANB angle 0.2° (12.4%), Wits appraisal 0.5 mm (19.5%), sagittal molar relationship 1.2 mm/0.1 cusp widths (21.8%/6.5%); soft tissue profile convexity excluding nose less than 0.1° (1.0%), overjet 1.8 mm (26.2%), overbite Class II:1 1.4 mm (44.7%), overbite Class II:2 1.0 mm (22.2%).	The scientific evidence concerning the stability of treatment outcomes is nonexistent for most fixed functional appliances for Class II correction except for Herbst appliance treatment. Even if evidence obtained from most of the selected studies is rather low, good dentoskeletal stability without clinically relevant changes was found for most variables.
Fonçatti et al. 2017 [31]	Recruitment period: Not reported. Trial design: Retrospective. Measurement methods: Cephalometric analysis.	All 24 (11 male, 13 female) patients were treated with Jasper jumper associated with fixed appliances for a mean period of 2.33 years. The mean initial age of the patients was 12.46 years, and the mean final age was 14.79 years. The mean age at the long-term posttreatment stage was 21.98 years. The mean long-term posttreatment period was 7.19 years. The control group comprised 15 subjects with normal occlusion.	Most dentoalveolar changes obtained with Jasper jumper followed by fixed appliances during treatment remained stable in the long term. However, apical base relationship, maxillary incisor anteroposterior position, and overjet demonstrated significant relapses in relation to the control group.	Active retention time should be increased in the posttreatment period.
Bock et al. 2018 [32]	Recruitment period: Not reported. Trial design: Retrospective. Measurement methods: Dental cast analysis.	Class II Division 1 patients who had received Herbst-MBA Tx and whose active Tx was completed at least 15 years ago. 52 patients (28 male, 24 female). Mean age: T0 = 12.8; T1 = 15.3; T2 = 17.8; T3 = 33.6. Data were compared with 31 untreated Class I controls.	In the pretreatment period, the following mean parameter values were found: PAR = 27.2, Class II MR = 0.7 cusp widths, overjet = 8.2 mm, and overbite = 4.1 mm. After treatment, the PAR index was 3.4. A Class I MR with normal overjet (2.3 mm) and overbite (1.3 mm) was observed. At recall, there was a mild increase to 8.2 points in the PAR index; this was mainly due to increased overjet and overbite values (3.6 and 2.8 mm), while the MR was stable.	Class II Division 1 correction showed very good long-term stability. Although mild changes occur in the posttreatment period, the long-term outcome is similar to that of untreated Class I controls. When evaluating these changes, however, it must be taken into account that 21 of the 52 study participants still wore fixed lower canine-to-canine retainers at T3 and no information on the underlying skeletal growth changes was available. Also, the final PAR index was 4.9 points lower in patients with retainers still in place at the follow-up when compared with those without retainers.
Bock et al. 2018 [33]	Recruitment period: Not reported. Trial design: Retrospective. Measurement methods: Dental cast analysis.	Class II Division 2 patients who had received Herbst-MBA Tx and whose active Tx was completed at least 15 years ago. 20 patients (12 male, 8 female). Mean age: T0 = 13.5; T1 = 15.7; T2 = 17.6; T3 = 33.9. Data were compared with historical untreated Class I controls.	Mean pretreatment values at the age of 14.4 years showed the following: PAR = 15.0, Class II MR = 0.8 cusp widths, and overbite = 5.3 mm. After treatment, a PAR index of 2.9 and a super Class I MR (-0.1) with normal overbite (1.2 mm) were observed. At recall, the PAR index increased by 5.9 points, mainly because of a 2.5-mm increase in overbite. The average MR remained Class I. The untreated controls exhibited similar findings for all variables.	The occlusal outcome of Class II Division 2 Herbst-MBA treatment exhibited very good long-term stability. Although mild posttreatment changes occurred, the long-term findings are similar to those of untreated Class I controls.

ANB, angle formed by the intersection of lines from points A and B to point N (Nasion); SNB, angle formed by the intersection of lines from points S (Sella) and B to point N (Nasion); ML/NSL, mandibular line/Nasion sella line; MBA, multibracket appliance; MR, molar relationship; PAR, peer assessment rating; TMJ, temporomandibular joint; Tx, treatment.

be used to "construct occlusion instead of destroying it"; and 3) changes resulting from normal craniofacial growth can alter the outcomes of orthodontic treatment.

Functional appliances have been used in orthodontics for more than 100 years and they have become quite popular worldwide [5]. The effect of fixed and removable functional appliances on the treatment of Class II malocclusion has been extensively investigated in recent decades [6–9]. Many studies [10–12] have sought to elucidate whether appliances manage to stimulate mandibular growth. Nevertheless, the lack of longitudinal studies on the stability of this treatment is rather intriguing.

Perhaps, we might even have an explanation to the paucity of long-term research into fixed functional appliances, given that their predecessor, the Herbst appliance, was reintroduced in 1979 [13], and since then, there have been variations of this appliance. Forsus, one of the most widely used appliances nowadays [14], was developed in 2002 [15] and has not had long-term assessments so far.

To fully understand the real effects of functional appliances on the growth of the jaws and profile, it is essential to study these effects at the completion of patient growth, when biases and confounding factors due to natural craniofacial changes become less impactful [16]. Considering that the long-term stability of treatment outcomes is key to successful orthodontic treatment, the aim of this narrative review was to summarize the available related evidence that has been published. Unfortunately, a systematic review was not advisable at this moment because of the small number of related publications and also because of major methodological problems among them. In this sense, this narrative review could be considered an attempt to answer various clinically relevant questions rather than a specific question. Systematic reviews are better suited to answer one specific narrow clinical question.

2. Narrative review

Assessment of the literature on the stability of Class II correction with functional appliances revealed a paucity of studies. Tables 1 and 2 present some longitudinal studies on removable and fixed functional appliances for Class II malocclusion correction. Our intention at first was to select articles that evaluated patients treated with functional appliances during their growth and reassess them after the age of 20 years (i.e., articles that assessed patients several years after the end of their craniofacial growth); however, while searching for published articles on this topic, we realized there were very few articles that met this criteria. Therefore, we decided to also consider articles that provided important information on longitudinal assessments, even if they did not meet our criteria.

Our overall question was: Why only assess longitudinal studies that consider treatment stability only after the age of 20 years?

Postpubertal growth has shown to produce dramatic alterations in aging in the craniofacial complex and it does not fully stop soon after puberty. According to Pancherz et al. [28], many clinicians consider the age of 20 years to be an indicator of completed skeletofacial growth. Nevertheless, skeletofacial growth still occurred in their patients [28] from 20 to 46 years; however, this publication could not verify exactly when that growth had actually taken place. Was growth distributed over the whole period, or did it only occur at the beginning of the period? In untreated subjects, Behrents [34] observed remaining skeletofacial growth after the age of 25 years in 50%, after 30 years in 24%, after 35 years in 9%, and after 40 years in 4% in the subjects he screened. Pecora et al. [35] found that growth continues up to middle adulthood (47 years), with different patterns between male and female individuals. Male individuals show anterior rotation of the mandible, whereas female individuals

demonstrate posterior mandibular rotation. Although the changes after adolescence are smaller than those during adolescence, the accumulation of these changes throughout life results in facial features that one can normally associate with orthodontic and orthopedic relapse.

The lack of longitudinal studies on functional appliances was also highlighted by Cacciatore et al. [16] in a recent systematic review. They analyzed data at two primary time points (older than 18 years and at the end of the growth period according to the Cervical Vertebral Maturation method) and at a secondary time point (at least 3 years after retention). Eight nonrandomized studies were included. The whole observational periods of included trials ranged from 4.7 to 10.2 years. They concluded that Class II functional appliances may be effective in correcting skeletal Class II malocclusion over the long term; however, the quality of the evidence was very low and the assessment of the clinical significance of the identified changes was minimal.

Comparison with normal expected craniofacial growth was another hindrance in the assessment of articles. Some used cephalometric measurements, whereas others used superimposition. Some articles did not have a control group and others included historical groups. Although historical control groups may present limitations, the use of historical controls was necessary because of the lack of ethical rationale to leave Class II patients untreated during a long-term observation interval. However, it is still possible to make some inferences about what has been published.

The Herbst appliance is the only fixed appliance that has been actually assessed longitudinally by Pancherz et al. [26–29,36]. They published a series of five articles describing the long-term changes that occurred in the first 14 patients from a sample of 22 with Class II Division 1 malocclusions consecutively treated with the banded Herbst appliance at ages 12 to 14 years. The subjects were reexamined after therapy at the ages of 20 years and 46 years. Examinations were analyzed before (T1) and after (T2) treatment, and at 6 years (T3) and 32 years (T4) after treatment. However, no untreated controls were used for comparison, and most of those patients did not have any further treatment other than just 6 months of mandibular bite jumping eventually followed by a period of activator appliance for retention purposes for 2 to 4 years.

Regarding removable appliances, only the Bionator and Activator have been investigated more consistently. The Fränkel appliance has also been assessed longitudinally by several authors, but patients have not been evaluated after the age of 20 years.

Curiously enough, Twin Block has not been evaluated in more robust longitudinal studies. Many short-term studies have been conducted, but none have assessed patients after the second decade of life.

Based on this review (Tables 1 and 2), we will try to answer a set of clinically relevant questions.

3. Is the long-term growth of the maxilla and mandible different after functional treatment compared with that of equivalent untreated controls?

It was identified that FR-2 [19,20], Bionator [21,22], and Jasper Jumper [31] had a minor or no long-term restraining effect on the position of the maxilla. Pancherz et al. [28] observed anterior maxillary growth (3.0 mm) 6 years after treatment with the Herbst appliance in patients aged 14 to 20 years. In the subsequent 26 years (patients aged 20 to 46 years), the maxilla grew 3.1 mm anteriorly.

Freeman et al. [19] and Angelieri et al. [20] used FR-2 and reported an increase in mandibular length by 3.0 mm and 3.7 mm, respectively, and Pavoni et al. [22] and Malta et al. [21] assessed Bionator and noted an increase in mandibular length by 5.5 mm and

3.3 mm, respectively, when compared with normal craniofacial growth. Pancherz et al. [28] observed that patients treated with the Herbst appliance had an anterior mandibular growth of 6.1 mm at 6 years after treatment (ages of 14 to 20 years). In the subsequent 26 years (ages 20 to 46 years), there was an anterior mandibular growth of 2.8 mm, but such growth was not different from the one observed in Class I patients [34]. However, other authors found different results. DeVincenzo [17] with Activator, Pavoni et al. [22] with Bionator when treatment was performed and completed before puberty, and Fonçatti et al. [31] with Jasper Jumper found no additional increase in long-term mandibular length, when they compared their results with the control groups.

Therefore, it may be summarized that in those years that follow the treatment with functional appliances, the maxilla and the mandible do grow anteriorly, with the mandible growing more than the maxilla, but there is a large variation in the magnitude of those changes. Also, longitudinal growth of the maxilla and of the mandible does not seem to differ after treatment with functional appliances when compared with untreated controls.

4. Is Class II treatment with functional appliances stable in the long term considering occlusal relationships and teeth alignment?

Several studies reviewed herein used the PAR index to assess the stability of occlusal changes after treatment with functional appliances. Examples are Ferrazzini [18] with Activator (T0 = 14.3; T2 = 3.65; T20 = 6.72), Jungbauer et al. [23] with Bionator (T0 = 18; T1 = 6.5; T2 = 12), Oliver et al. [25] with Twin Block (T1 = 39.91; T2 = 7.50; T3 = 11.94), Bock et al. [32] with Herbst (T0 = 27.2; T1 = 3.4; T3 = 8.2), and also Bock et al. [33] with Herbst (T0 = 15; T1 = 2.9; T3 = 5.9). Their results suggest that most of the changes obtained during treatment were maintained for several years.

The relapse of anterior crowding was also evaluated (in millimeters) by some authors. Ferrazzini [18] with Activator (T0 = 1.33, T1 = 0.88, T20 = 2.05), Jungbauer et al. [23] with Bionator (T0 = 2.3;

T1 = 2.0; T2 = 3.7), Keski-Nisula et al. [24] with Eruption Guidance Appliance (T1 = 35%; T2 = 2%; T3 = 14%), and Pancherz and Bjerklin [27] with Herbst (T1 = 3.4; T2 = 3.0; T3 = 4.1; T4 = 5.1). In general, there was an increase in lower incisor irregularity after the long-term follow-up.

Considering molar relationship, Jungbauer et al. [23] with Bionator, Keski-Nisula et al. [24] with Eruption Guidance Appliance, Oliver et al. [25] with Twin Block, and Pancherz et al. [26] and Bock et al. [32,33] with Herbst treatment noted that first molar relationship significantly improved after treatment and remained reasonably stable in the long term.

In summary, the occlusal outcome of Class II functional treatment mostly exhibited long-term stability. Although mild post-treatment changes occurred, they were most likely due to physiological aging processes and were not likely associated with treatment relapse. Long-term retention in the lower jaw would be particularly beneficial for maintaining overjet, overbite, and alignment stability.

5. What factors influence the stability of functional Class II treatment?

Oliver et al. [25] studied the Twin Block appliance followed by preadjusted edgewise appliances and tried to identify what factors influenced their stability. They used logistic regression and did not identify any factors that significantly influenced posttreatment changes; however, there was a weak association with change in overjet.

Overall, like other orthodontic treatment modalities [37], the use of functional appliances for Class II correction does not guarantee alignment stability over the long term. Class II molar and overjet relapses can be explained by a combination of tooth movement (upper teeth inclined forward and lower teeth inclined posteriorly) and an unfavorable posttreatment maxillomandibular growth pattern, especially when combined with unstable interdigitation of the teeth [28]. A stable occlusion with good

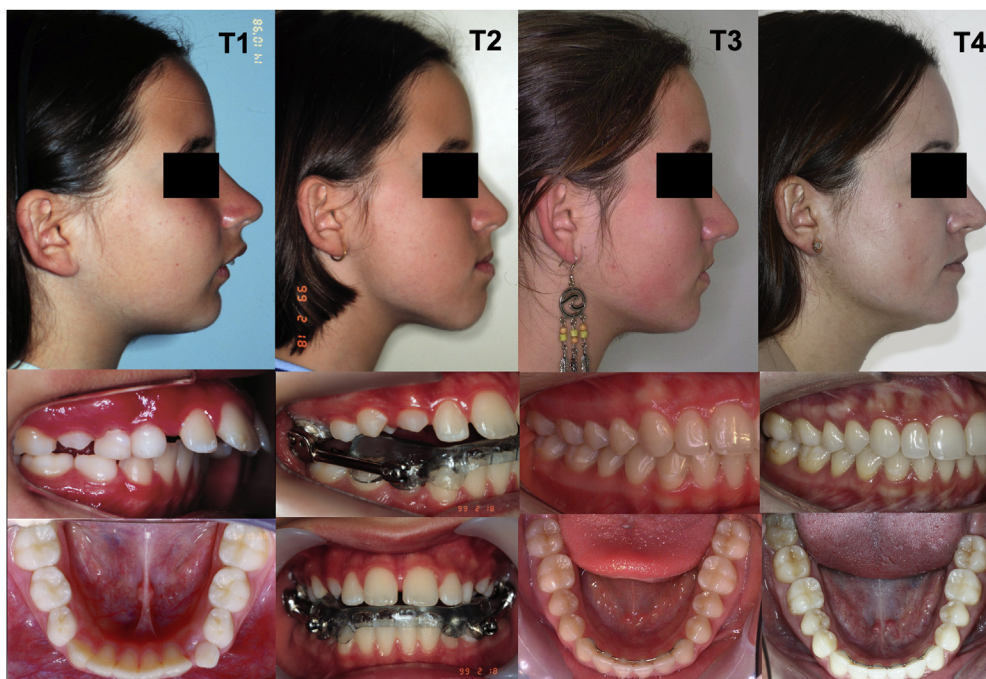


Fig. 1. Patient treated with a Herbst appliance with stainless steel crowns on the maxillary first molars and a removable mandibular occlusal coverage acrylic splint. T1 = before treatment; T2 = immediately after Herbst appliance placement; T3 = at the end of fixed appliance treatment (age 14); T4 = 17 years after treatment (age 31).

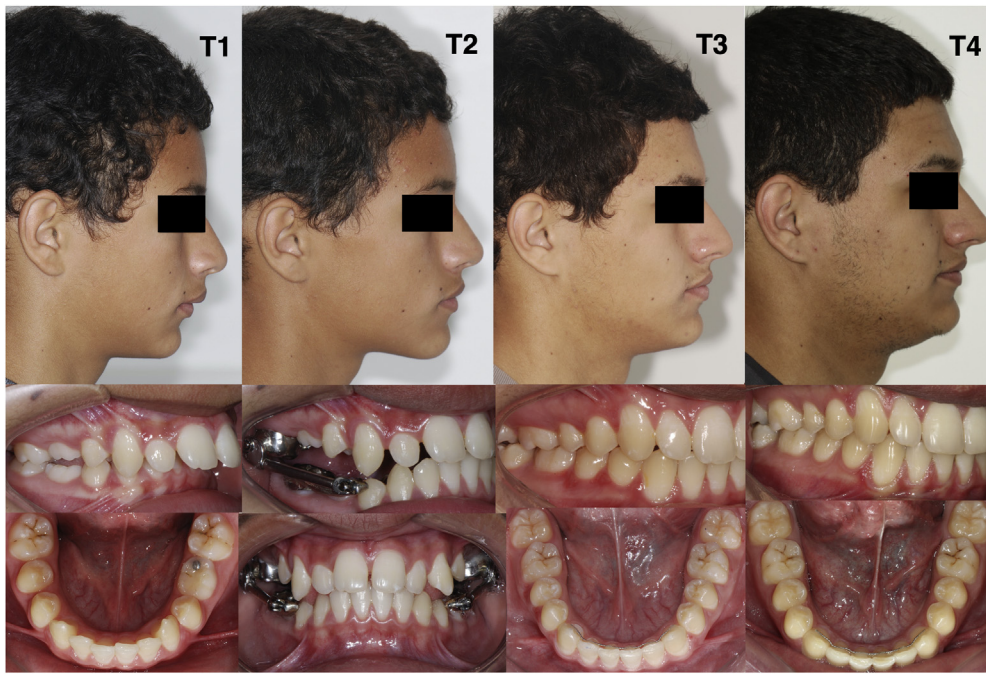

Fig. 2. Patient treated with cantilever Herbst appliance. T1 = before treatment; T2 = immediately after Herbst appliance placement; T3 = at the end of fixed appliance treatment (age 15); T4 = 5 years after treatment (age 20).

intercuspal in the posterior arches will likely preserve a Class I occlusion after treatment by dentoalveolar compensatory mechanisms [38] (Figs. 1–4).

6. Is permanent retention indicated?

Deterioration in mandibular incisor alignment during the second, third, and fourth decades of life has been reported in several

studies of untreated subjects [39,40] and in subjects with previous orthodontic treatment followed through retention periods [41]. Such changes are now recognized to be a normal rather than an exceptional occurrence throughout life.

Several studies assessed in this review revealed a relapse of incisor alignment after the long-term follow-up, which was most likely associated with a significant decrease in both lower arch perimeter and intercanine width. Long-term changes were most

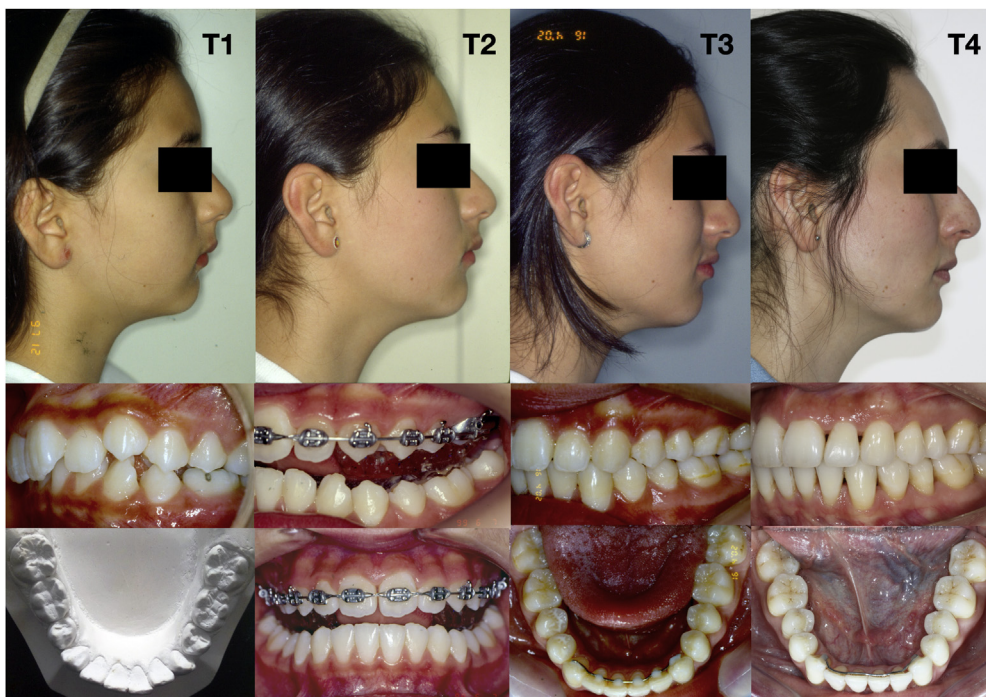


Fig. 3. Patient treated with Bionator. T1 = before treatment; T2 = at the end of Bionator treatment; T3 = at the end of fixed appliance treatment (age 14); T4 = 18 years after treatment (age 31).

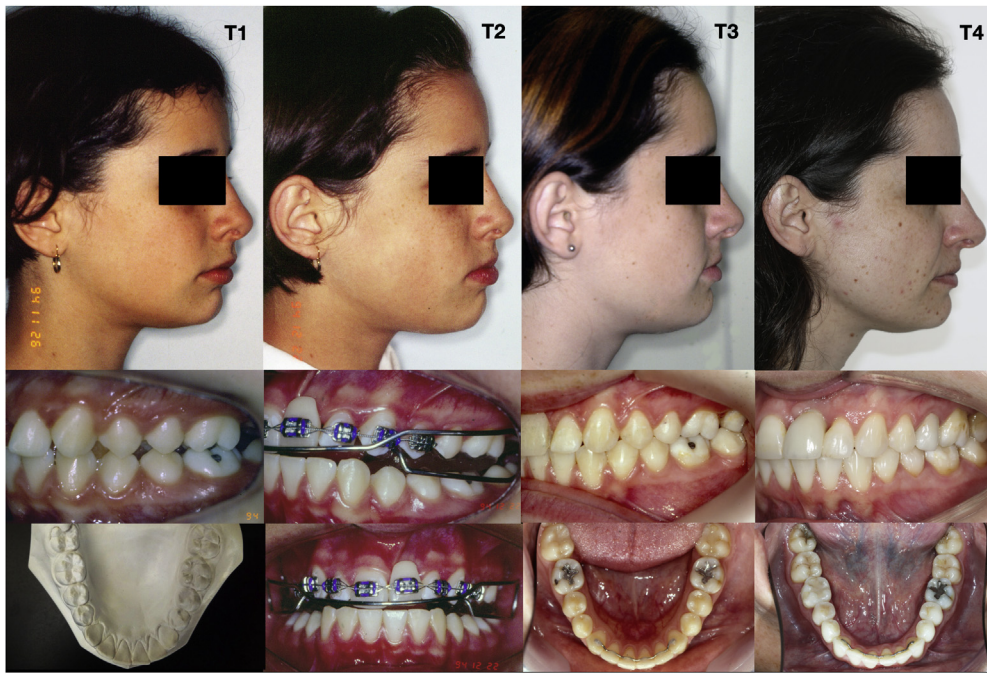

Fig. 4. Patient treated with Bionator. T1 = before treatment; T2 = immediately after Bionator placement; T3 = at the end of fixed appliance treatment (age 16); T4 = 20 years after treatment (age 36).

likely due to physiological aging processes and were not likely associated with functional appliance treatment, as they also occurred in Class I subjects.

Thus, the use of fixed retention in the lower arch [42] or in both arches [43], and part-time use of an upper removable retainer could be used to prevent relapse, as also used in other treatment modalities. Considering the lack of high-quality evidence about the stability of corrections with removable and fixed functional appliances, our retention approach will be strongly influenced by our own clinical experience and expertise with different retainers, as well as by patients' values, expectations, and circumstances [44,45].

In summary, the relapse of dental changes after treatment with functional appliances could be prevented with fixed retainers on the upper and lower anterior teeth and with removable retainers on the upper arch. No specific intermaxillary retention approach has been proven to be consistently effective yet.

7. Are patients treated with functional appliances more likely to develop temporomandibular joint disorder over the long term?

Many short-term studies [9,46] have been conducted on the effect of functional appliances on the temporomandibular joint (TMJ), assessing the shape and position of the condyle, of the fossa, and of the articular disc; however, few studies have carried out a long-term assessment. Moreover, there is little information linking functional appliances to the development of temporomandibular disorders, especially in the long run.

In the only long-term study that assessed this, Pancherz et al. [29] found signs of osteoarthritis in one patient 6 years after Herbst therapy. In the 32-year follow-up, two additional patients had developed signs of osteoarthritis. In the 6-year follow-up, TMJ clicking was present in two patients, although none of them reported TMJ pain. In the 32-year follow-up, six patients had TMJ clicking and one patient had TMJ pain. Pancherz et al. [29]

concluded that very long term follow-up study after Herbst therapy revealed only minor TMJ disorders and these findings corresponded with those observed in the general population.

It would be interesting to know whether there is any difference in the effects on the TMJ in the long term, comparing removable functional appliances with fixed appliances. Among fixed appliances, it also would be interesting to assess whether there is any difference between rigid appliances (e.g., Herbst and MARA) and hybrid appliances (e.g., Forsus and PowerScope). According to Arici et al. [47], in the treatment with rigid fixed appliances, such as Herbst and MARA, the condyle cannot return to its seated position, whereas the Forsus nitinol flat spring (or the Forsus fatigue-resistant spring), a flexible fixed appliance, allows the patient to function in centric occlusion. This suggests that the use of Forsus appliance might enable better posttreatment condylar repositioning [9].

In summary, it appears that patients treated with functional appliances are not likely to develop TMJ disorders over the long term that differ from those observed in the general population.

8. Clinical implications and future research

Given that mandibular growth is larger than that of the maxilla from the end of adolescence and that, in general, molar relationship correction by functional appliances is stable, we do not believe it is necessary to use long-term active retention with a removable functional appliance or with an extraoral appliance. Retention should be aimed at avoiding undesirable tooth movements. On the other hand, active retention [48,49] would be used to move the teeth that may not have finished in an ideal position. An Activator or a Bionator appliance could be indicated as active retainer if an occlusal correction of more than 3 mm is necessary, as in the case without full correction of Class II malocclusion, if strong interdigitation was not attained or if relapse occurred during the fixed appliance follow-up treatment [3].

The timing of skeletal correction appears to influence skeletal and tooth movements but not the stability of these movements per se. Therefore, as far as long-term stability is concerned, there is no difference in whether the patient is treated before or during the pubertal growth spurt.

In addition, more robust longitudinal studies on the effect of different functional appliances on Class II malocclusion treatment should be done. Randomized controlled trials (RCTs) comparing treated patients with untreated subjects (not historical controls) should be carried out. But because of significant attrition, participation 10 years after the RCTs are completed, expecting to have meaningful long-term samples from RCTs is utopic. Well-conducted retrospective cohort studies are needed for long-term assessment. Proper matching of initial malocclusion characteristics is essential in those cases.

The issue of long-term follow-up of untreated cases is controversial. At the same time, not every malocclusion is treated.

A consensus should be reached on the clinically important measurements to be used for inclusion in the study and assessment of the effects. Few linear measurements to evaluate the position of the maxilla and mandible, and the relationship between these jaws, seem to be more appropriate [16]. We also suggest comparing different retention methods for this type of treatment. Consideration of patient-oriented outcomes is also paramount.

9. Conclusions

1. Longitudinal growth of the maxilla and of the mandible does not seem to differ after treatment with functional appliances when compared with untreated controls (low level of certainty).
2. Skeletal corrections achieved with removable or fixed functional appliances seem to be overall stable in the long term. Dentoalveolar relapse is more frequent and very similar to what occurs with other types of orthodontic treatment (low level of certainty).
3. Class II molar and overjet relapses can be likely explained by a combination of tooth movement (upper teeth moved anteriorly and lower teeth moved posteriorly) and an unfavorable post-treatment maxillomandibular growth pattern, especially when combined with unstable interdigitation of the posterior teeth (low level of certainty).
4. Relapse of dental changes after treatment with functional appliances could be prevented with fixed retainers on the upper and lower anterior teeth and with removable Hawley appliances or vacuum-formed retainers on the upper arch. No specific intermaxillary retention approach has been assessed yet (low level of certainty).
5. The scarce longitudinal studies performed so far suggest that patients treated with functional appliances are unlikely to develop TMJ disorders (low level of certainty).
6. Information on the longitudinal assessment of the effect of functional appliances on soft tissue profile is still lacking. Patient important outcomes, such as perceived attractiveness, self-esteem, and oral health-related quality of life, should be assessed as well.

References

- [1] Angle EH. Classification of malocclusion. *Dental Cosmos* 1899;41:248–64.
- [2] Thilander B. Biological basis for orthodontic relapse. *Semin Orthod* 2000;6:195–205.
- [3] Proffit WR. *Contemporary orthodontics*. 4th ed. St Louis: Mosby; 2007. p. 617–31.
- [4] Rogers AP. Making facial muscles our allies in treatment and retention. *Dental Cosmos* 1922;64:711–30.
- [5] Johnston Jr LE. Growing jaws for fun and profit: a modest proposal. In: Monograph 35. Craniofacial Growth Series. Ann Arbor, MI: Center for Human Growth and Development; University of Michigan; 1999.
- [6] Moro A, Borges SW, Spada PP, et al. Twenty-year clinical experience with fixed functional appliances. *Dental Press J Orthod* 2018;23:87–109.
- [7] Flores-Mir C, Major PW. A systematic review of cephalometric facial soft tissue changes with the Activator and Bionator appliances in Class II division 1 subjects. *Eur J Orthod* 2006;28:586–93.
- [8] Silva JFE, Gerszewski C, Moresca RC, Correr GM, Flores-Mir C, Moro A. Retrospective study of clinical complications during orthodontic treatment with either a removable mandibular acrylic splint Herbst or with a cantilever Herbst. *Angle Orthod* 2015;85:64–71.
- [9] Kyburz KS, Eliades T, Papageorgiou SN. What effect does functional appliance treatment have on the temporomandibular joint? A systematic review with meta-analysis. *Prog Orthod* 2019;20:32.
- [10] Johnston Jr LE. Functional appliances: a mortgage on mandibular position. *Aust Orthod J* 1996;14:154–7.
- [11] Cozza P, Baccetti T, Franchi L, De Toffol L, McNamara Jr JA. Mandibular changes produced by functional appliances in Class II malocclusion: a systematic review. *Am J Orthod Dentofacial Orthop* 2006;129:599.e1–599.e12.
- [12] Zymperdikas VF, Koretsi V, Papageorgiou SN, Papadopoulos MA. Treatment effects of fixed functional appliances in patients with Class II malocclusion: a systematic review and meta-analysis. *Eur J Orthod* 2016;38:113–26.
- [13] Panchez H. Treatment of Class II malocclusion by jumping the bite with the Herbst appliance: a cephalometric investigation. *Am J Orthod* 1979;76:423–42.
- [14] Keim RG, Gottlieb EL, Vogels DS, Vogels PB. JCO study of orthodontic diagnosis and treatment procedures, Part 1: results and trends. *J Clin Orthod* 2014;48:607–30.
- [15] Vogt W. The Forsus fatigue resistant device. *J Clin Orthod* 2006;50:365–77.
- [16] Cacciato G, Ugolini A, Sforza C, Gbinigie O, Plüddemann A. Long-term effects of functional appliances in treated versus untreated patients with Class II malocclusion: a systematic review and meta-analysis. *PLoS One* 2019;14:e0221624.
- [17] DeVincenzo JP. Changes in mandibular length before, during, and after successful orthopedic correction of Class II malocclusions, using a functional appliance. *Am J Orthod Dentofacial Orthop* 1991;99:241–57.
- [18] Ferrazzini G. Class II/2 malocclusion: early treatment with removable appliances and stability after 20 years. *Schweiz Monatsschr Zahnmed* 2008;118:814–9.
- [19] Freeman DC, McNamara Jr JA, Baccetti T, Franchi L, Fränkel C. Long-term treatment effects of the FR-2 appliance of Fränkel. *Am J Orthod Dentofacial Orthop* 2009;135:570.e1–6.
- [20] Angelieri F, Franchi L, Cevidanes LHS, Scanavini MA, McNamara Jr JA. Long-term treatment effects of the FR-2 appliance: a prospective evaluation 7 years post-treatment. *Eur J Orthod* 2014;36:192–9.
- [21] Malta LA, Baccetti T, Franchi L, Faltin Jr K, McNamara Jr JA. Long-term dentoalveolar effects and facial profile changes induced by bionator therapy. *Angle Orthod* 2010;80:10–7.
- [22] Pavoni C, Lombardo EC, Lione R, et al. Treatment timing for functional jaw orthopaedics followed by fixed appliances: a controlled long-term study. *Eur J Orthod* 2018;40:430–6.
- [23] Jungbauer R, Koretsi V, Proff P, Rudzki I, Kirschneck C. Twenty-year follow-up of functional treatment with a bionator appliance: a retrospective dental cast analysis. *Angle Orthod* 2020;90:205–15.
- [24] Keski-Nisula K, Keski-Nisula L, Varrelä J. Class II treatment in early mixed dentition with the eruption guidance appliance: effects and long-term stability. *Eur J Orthod* 2020;42:151–6.
- [25] Oliver GR, Pandis N, Fleming PS. A prospective evaluation of factors affecting occlusal stability of Class II correction with Twin-block followed by fixed appliances. *Am J Orthod Dentofacial Orthop* 2020;157:35–41.
- [26] Panchez H, Bjerklín K, Lindskog-Stokland B, Hansen K. Thirty-two-year follow-up study of Herbst therapy: a biometric dental cast analysis. *Am J Orthod Dentofacial Orthop* 2014;145:15–27.
- [27] Panchez H, Bjerklín K. Mandibular incisor inclination, tooth irregularity, and gingival recessions after Herbst therapy: a 32-year follow-up study. *Am J Orthod Dentofacial Orthop* 2014;146:310–8.
- [28] Panchez H, Bjerklín K, Hashemi K. Late adult skeletofacial growth after adolescent Herbst therapy: a 32-year longitudinal follow-up study. *Am J Orthod Dentofacial Orthop* 2015;147:19–28.
- [29] Panchez H, Sal H, Bjerklín K. Signs and symptoms of TMJ disorders in adults after adolescent Herbst therapy: a 6-year and 32-year radiographic and clinical follow-up study. *Angle Orthod* 2015;85:735–42.
- [30] Bock NC, von Bremen J, Ruf S. Stability of Class II fixed functional appliance therapy: a systematic review and meta-analysis. *Eur J Orthod* 2016;38:129–39.
- [31] Fonçatti CF, Castanha Henriques JF, Janson G, Caldas W, Garib DG. Long-term stability of Class II treatment with the Jasper jumper appliance. *Am J Orthod Dentofacial Orthop* 2017;152:663–71.
- [32] Bock NC, Saffar M, Hudel H, et al. Long-term (≥ 15 years) post-treatment changes and outcome quality after Class II:1 treatment in comparison to untreated Class I controls. *Eur J Orthod* 2018;40:206–13.
- [33] Bock NC, Saffar M, Hudel H, et al. Outcome quality and long-term (≥ 15 years) stability after Class II:2 Herbst-multibracket appliance treatment in comparison to untreated Class I controls. *Eur J Orthod* 2018;40:488–95.

- [34] Behrents RG. Growth in the aging craniofacial skeleton. In: Monograph 17. Craniofacial Growth Series. Ann Arbor, MI: Center for Human Growth and Development, University of Michigan; 1985.
- [35] Pecora NG, Baccetti T, McNamara Jr JA. The aging craniofacial complex: a longitudinal cephalometric study from late adolescence to late adulthood. *Am J Orthod Dentofacial Orthop* 2008;134:496–505.
- [36] Pancherz H, Bjerklin K. The Herbst appliance 32 years after treatment. *J Clin Orthod* 2015;49:442–51.
- [37] Little RM. Stability and relapse of mandibular anterior alignment: University of Washington studies. *Semin Orthod* 1999;5:191–204.
- [38] Solow B. The dentoalveolar compensatory mechanism: background and clinical implications. *Br J Orthod* 1980;7:145–61.
- [39] Richardson ME. A review of changes in lower arch alignment from seven to fifty years. *Semin Orthod* 1999;5:151–9.
- [40] Massaro C, Miranda F, Janson G, et al. Maturational changes of the normal occlusion: a 40-year follow-up. *Am J Orthod Dentofacial Orthop* 2018;154:188–200.
- [41] Schütz-Fransson U, Lindsten R, Bjerklin K, Bondemark L. Mandibular incisor alignment in untreated subjects compared with long-term changes after orthodontic treatment with or without retainers. *Am J Orthod Dentofacial Orthop* 2019;155:234–42.
- [42] Booth FA, Edelman JM, Proffit WR. Twenty-year follow-up of patients with permanently bonded mandibular canine-to-canine retainers. *Am J Orthod Dentofacial Orthop* 2008;133:70–6.
- [43] Wouters C, Lamberts TA, Kuijpers-Jagtman AM, Renkema AM. Development of a clinical practice guideline for orthodontic retention. *Orthod Craniofac Res* 2019;22:69–80.
- [44] Swidi AJ, Taylor RW, Tadlock LP, Buschang PH. Recent advances in orthodontic dental retention methods: a review article. *J World Fed Orthod* 2018;7:6–12.
- [45] Littlewood SJ. Evidence-based retention: where are we now? *Semin Orthod* 2017;23:229–36.
- [46] Cheib Vilefort PL, Farah LO, Gontijo HP, et al. Condyle-glenoid fossa relationship after Herbst appliance treatment during two stages of craniofacial skeletal maturation: a retrospective study. *Orthod Craniofac Res* 2019;22:345–53.
- [47] Arici S, Akan H, Yakubov K, Arici N. Effects of fixed functional appliance treatment on the temporomandibular joint. *Am J Orthod Dentofacial Orthop* 2008;133:809–14.
- [48] Lavergne J. Diagnostic orthodontique et informatique. *Rev Orthop Dento Faciale* 1992;26:295–307.
- [49] Nanda RS, Nanda SK. Considerations of dentofacial growth in long-term retention and stability: is active retention needed. *Am J Orthod Dentofacial Orthop* 1992;101:297–302.