



# Distal movement of maxillary molars in nongrowing patients with the skeletal anchorage system

Junji Sugawara,<sup>a</sup> Reiko Kanzaki,<sup>b</sup> Ichiro Takahashi,<sup>c</sup> Hiroshi Nagasaka,<sup>d</sup> and Ravindra Nanda<sup>e</sup>

Sendai, Japan, and Farmington, Conn

**Introduction:** It is now possible to predictably move maxillary molars distally in nongrowing patients with the skeletal anchorage system (SAS) and to improve malocclusions without having to extract the premolars and regardless of the patient's compliance. The purposes of this study were to investigate the amount of distal movement of the maxillary first molars, the type of movement, the difference between actual and predicted amounts of distalization, and the relationship between the amount of distalization and age. **Methods:** Twenty-five nongrowing patients (22 female, 3 male) successfully treated with the SAS were the subjects in this study. The amount and the type of distalization, the difference between predicted and resulting amounts of distalization, and the relationship between the patient's age and the amount of distalization were analyzed with wide-opening cephalometric radiographs. **Results:** The average amount of distalization of the maxillary first molars was 3.78 mm at the crown level and 3.20 mm at the root level. The amount of distalization at the crown level was significantly correlated with the average value of treatment goals (3.60 mm). **Conclusions:** The maxillary molars were predictably distalized in accordance with the individualized treatment goals without regard to patient age and extraction of the third or second molars. The SAS is a viable noncompliance modality to move maxillary molars for distally correcting maxillary protrusions and malocclusions characterized by maxillary incisor crowding. (Am J Orthod Dentofacial Orthop 2006;129:723-33)

Premolar-extraction treatment with a multi-bracketed system and reinforced anchorage has been a common modality for correcting maxillary incisor crowding or Class II malocclusion in nongrowing patients, because it had been very difficult to move the maxillary molars distally after full eruption of the maxillary second molars. In addition, headgear that has been frequently applied to distalize the maxillary molars in adolescent patients was seldom an option for adults because of esthetic and compliance concerns.<sup>1-3</sup> To solve these problems, various intraoral noncompliance appliances for maxillary molar distalization have

been introduced since the 1980s and evaluated.<sup>4-35</sup> It was possible to distalize the maxillary molars with those appliances, but 2 negative effects have been reported: (1) anchorage loss of the maxillary premolars and flaring of the incisors commonly happened in reaction to the molar distalization, and (2) because the distalized molars must be used as part of anchorage during retraction of the premolars and the anterior teeth, a considerable amount of relapse can occur.<sup>33</sup>

To remedy the problems of noncompliance appliances, intraoral distalizing mechanics combined with palatal implants have attracted attention,<sup>36</sup> because it has become possible to distalize the maxillary molars by using absolute anchorage more efficiently than ever.<sup>37</sup>

The skeletal anchorage system (SAS) that we developed is a noncompliance appliance that uses a similar concept as the palatal implant system. However, from a mechanical point of view, the SAS differs from the palatal implant system.<sup>38,39</sup> The SAS consists of titanium anchor plates and monocortical screws that are temporarily placed in either the maxilla or the mandible, or in both, as absolute anchorage units for adult orthodontics. The SAS has been used as a multipurpose modality in combination with a multi-bracketed appliance, and it is possible to move maxillary molars distally with ease.

This study was conducted to verify the effi-

<sup>a</sup>Associate professor, Division of Orthodontics and Dentofacial Orthopedics, Graduate School of Dentistry, Tohoku University, Sendai, Japan.

<sup>b</sup>Research associate, Division of Orthodontics and Dentofacial Orthopedics, Graduate School of Dentistry, Tohoku University, Sendai, Japan.

<sup>c</sup>Lecturer, Division of Orthodontics and Dentofacial Orthopedics, Graduate School of Dentistry, Tohoku University, Sendai, Japan.

<sup>d</sup>Clinical professor, Division of Maxillofacial Surgery, Graduate School of Dentistry, Tohoku University, Sendai, Japan.

<sup>e</sup>UConn orthodontic alumni endowed chair, professor and head, Department of Craniofacial Sciences, chair, Division of Orthodontics, University of Connecticut, Farmington.

Reprint requests to: Junji Sugawara, Division of Orthodontics and Dentofacial Orthopedics, Tohoku University Graduate School of Dentistry, 4-1 Seiryomachi, Aoba-ku, Sendai, 980-8575, Japan; e-mail, sugahara@mail.tains.tohoku.ac.jp. Submitted, August 2004; revised and accepted, August 2005.

0889-5406/\$32.00

Copyright © 2006 by the American Association of Orthodontists.

doi:10.1016/j.ajodo.2005.08.036

**Table.** Sample characteristics

Patient	Sex	Age	Facial type	Extraction site	Treatment goal (mm)	Treatment period (mo)
1	F	15 y 2 mo	Class II, ave	Rs8/Ls8	3.3	29
2	F	15 y 3 mo	Class II, ave	Rs7/Ls7	4.3	36
3	M	15 y 5 mo	Class II, long (open)	Rs7/Ls7	3.5	13
4	F	15 y 9 mo	Class III, long	Rs8/Ls8	3.3	13
5	F	15 y 11 mo	Class II, long (open)	Non-ext.	3.0	18
6	F	16 y 0 mo	Class III, long	Rs7/Ls7	4.5	12
7	F	16 y 4 mo	Class II, ave (deep)	Rs8/Ls8	5.5	16
8	F	19 y 2 mo	Class II, long	Rs7/Ls7	3.5	18
9	F	19 y 5 mo	Class II, long (open)	Rs8/Ls8	4.2	18
10	F	19 y 5 mo	Class III, long (open)	Rs7/Ls7	5.0	27
11	M	19 y 8 mo	Class III, long (open)	Rs8/Ls8	2.0	20
12	F	20 y 5 mo	Class III, ave	Missing	2.5	26
13	F	20 y 10 mo	Class II, long	Rs7/Ls7	3.0	15
14	F	21 y 6 mo	Class II, long	Rs8/Ls8	2.3	15
15	F	24 y 7 mo	Class III, ave	Rs8/Ls8	2.0	18
16	F	25 y 3 mo	Class II, long (open)	Rs8/Ls8	3.0	8
17	F	26 y 7 mo	Class II, long	Rs8 missing/Ls8	6.5	30
18	F	27 y 1 mo	Class II, long (open)	Rs8/Ls8	3.0	11
19	F	27 y 8 mo	Class I, long (open)	Rs8/Ls8	6.3	30
20	M	28 y 9 mo	Class III, long	Rs8/Ls8	2.0	14
21	F	31 y 5 mo	Class II, long (open)	Rs8/Ls8	2.0	18
22	F	33 y 11 mo	Class III, long	Missing	4.0	18
23	F	37 y 9 mo	Class II, ave	Missing	3.5	17
24	F	39 y 0 mo	Class II, long (open)	Missing	3.0	15
25	F	45 y 5 mo	Class II, long	Missing	4.0	22

F, Female; M, male; *ave*, average facial type; Rs, right side; Ls, left side; 7, second molar; 8, third molar.

ciency of the SAS. Its purposes were to investigate the amount of distal movement of the maxillary first molars, the type of movement, the difference between actual and predicted amounts of distalization, and the relationship between the amount of distalization and age.

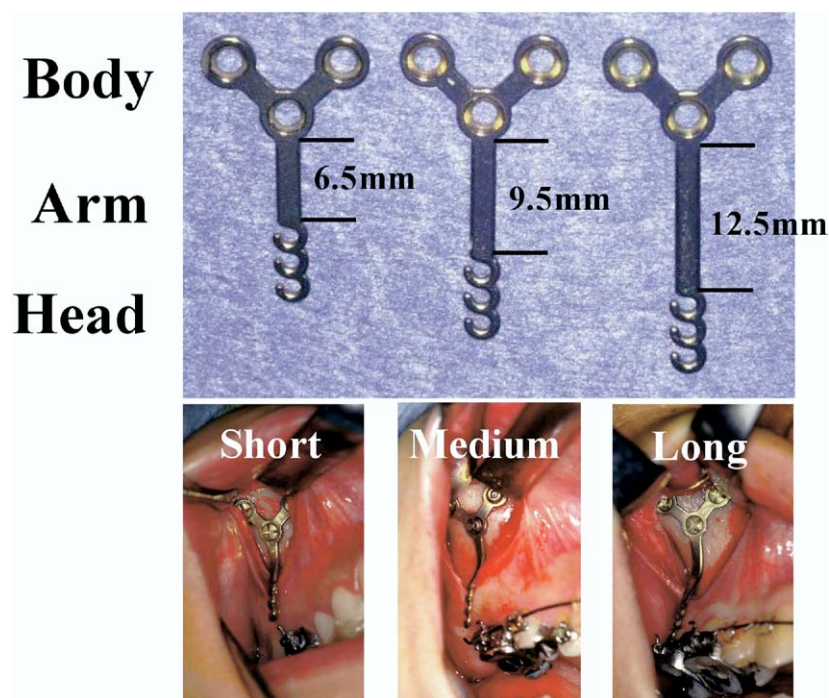
#### MATERIAL AND METHODS

Twenty-five nongrowing patients (22 female, 3 male) who had undergone SAS treatment at Tohoku University Dental Hospital, Sendai, Japan, were selected as subjects in this study. Twenty-two patients were treated by 1 clinician (J.S.), and 3 patients were managed by residents under his supervision. All subjects met the following criteria for case selection: (1) it was cephalometrically confirmed that they were nongrowing at least in terms of the maxillary growth before treatment, (2) there was sufficient space behind the first molar for the second and third molars after distalization, (3) individualized treatment goals were feasible according to the cephalometric and occlusogram predictions, and (4) treatment could be performed by using symmetrical distalization mechanics. The sample characteristics are shown in the Table. The most common complaint of these patients was maxillary incisor crowding. Their average age at the beginning of treat-

ment was 23 years 11 months (range, 15 years 2 months to 45 years 5 months). The third molars were bilaterally extracted in 12 patients and bilaterally missing in 5. The bilateral second molars were extracted in 6 patients because of anticipated difficulty in extracting the maxillary third molars. The average SAS treatment period was about 19 months (range, 8 to 36 months).

Figure 1 shows the anchor plates (Orthoanchor SMAP, Dentsply-Sankin, Tokyo, Japan) that were newly developed and used for distalization and intrusion of the maxillary molars.<sup>39</sup> The plates were made of pure titanium and therefore were suitable for osseointegration and tissue integration. In addition, they were sufficiently strong to resist the usual orthodontic forces, even at the headgear force level, and could be bent with ease for fitting into the bone contour of the implantation site.

The head portion was intraorally exposed and positioned outside the dentition, so that it never disturbed the distalization of the maxillary molars. Each head portion had 3 continuous hooks for easier application of the orthodontic force vectors. The arm portion was transmucosal and had 3 graduated lengths—short (6.5 mm), medium (9.5 mm), and long (12.5 mm)—to compensate for individual morphological



**Fig 1.** Orthodontic titanium anchor plates for distal movement of maxillary molars.

differences (Fig 1). The body portion was positioned subperiosteally.

The implantation sites of the anchor plates required sufficiently thick cortical bone, at least 2 to 3 mm, to enable fixation of the anchor plates with monocortical miniscrews. The screws were also made of pure titanium. Each screw had a head with a tapered inside square and self-tapping thread. The diameter of the screw was 2 mm, and the available length was 5 mm.

The anchor plates were placed at the zygomatic buttress to distalize the maxillary molars (Fig 1). Although the lateral wall of the maxilla was too thin to hold the screws of the anchor plates, the bone of the zygomatic buttress was thick enough.

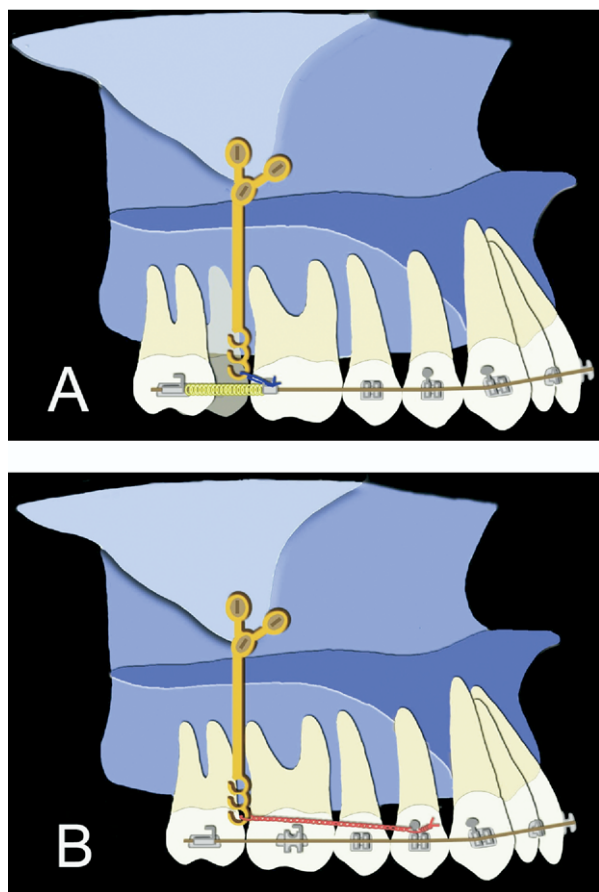
The operation was carried out under local anesthesia administered with intravenous sedation. First, a mucoperiosteal incision was made at the buccal vestibule of the implantation site. A mucoperiosteal flap was elevated after subperiosteal ablation and the surface of the cortical bone at the implantation site was exposed. The anchor plate was selected according to the distance between the implantation site and the dentition. This should be quite clear from the panoramic x-ray film taken before surgery. The selected plate was contoured to fit the bone surface. Then a pilot hole was drilled, and a self-tapping and monocortical screw was inserted. After the placement of the remaining screws, the anchor plate was then firmly attached to the bone

surface. The wound was closed and sutured with absorbable thread. The surgery took 10 to 15 minutes for each anchor plate.

Orthodontic force was usually applied about 3 weeks after the implantation surgery, after postsurgical management, but it was not necessary to wait for the osseointegration of the titanium screws and plates. All anchor plates were removed immediately after debonding.

Most patients who underwent SAS placement had mild to moderate facial swelling for several days after surgery. Infection occurs in less than 10% of patients. Mild infections can be controlled by antiseptic mouthwash and careful brushing techniques. In more severe cases, antibiotics are required.

Figure 2 shows the 2 representative SAS mechanics for distalization of the maxillary molars. One is single molar distalization (Fig 2, A), and the other is en-masse molar distalization (Fig 2, B) with sliding mechanics. All subjects were bonded with preadjusted multi-bracketed appliances with 0.022-in slots. Heat-treated 0.018 x 0.025-in blue Elgiloy (Rocky Mountain Orthodontics, Denver, Colo) wires were used as the main archwires for distalization of the maxillary molars. The orthodontic forces were approximately 200 gf for single molar distalization and approximately 500 gf for en-masse molar distalization. Orthodontic forces were mostly provided by nickel-titanium open-coil springs (Tomy International,



**Fig 2.** SAS biomechanics for distal movement of maxillary molars. **A**, Single molar distal movement; **B**, en-masse molar distal movement.

Tokyo, Japan) or elastic chain modules (Pro-Chain, Dentsply-Sankin).

### Cephalometric measurements

Lateral cephalometric radiographs in wide-opening mouths were used in this study, because the crown shapes of the maxillary first molars could be clearly identified without being obscured by the opposing teeth. The radiographs were taken before treatment and immediately after debonding in all subjects (Fig 3, A). Cephalometric radiographs were traced, and the cranio-maxillary tracings were carefully superimposed by using such stable anatomical structures as the cranium, anterior cranial base, and fine structures in the maxilla (Fig 3, B). The tracings of the left and right first molars were averaged.

Figure 4 shows the reference planes and landmarks for determining the distal movement of the maxillary first molars. The initial occlusal plane, which was defined by the first molar and the maxillary central

incisor, served as the x-axis, and the y-axis was a perpendicular line drawn from the pterygomaxillary fissure. C1 and C2 were the most distal points of the maxillary first-molar crown before treatment and at debonding, respectively. Similarly, R1 and R2 were the most distal points of the maxillary first-molar root before treatment and at debonding, respectively. The x-axes of each landmark were measured with calipers at a precision of 0.1 mm, and the amount of posterior displacement at the crown (C1-C2) and root (R1-R2) were calculated. The type of tooth movement was evaluated by the crown and root movement ratio. Then the difference from the predicted amount of the crown distalization (treatment goals) was assessed. In addition, the relationships among the amount of posterior displacement of the crown, patients' ages before treatment, and extraction site of the posterior teeth were evaluated.

All cephalometric tracings and measurements were performed by 1 researcher (J.S.), and the intra-individual method error did not exceed 0.2 mm.

The Pearson correlation coefficient test was applied to evaluate the relationships between the amount of posterior displacement at the crown and root levels, and the difference from the predicted amount of crown movement.

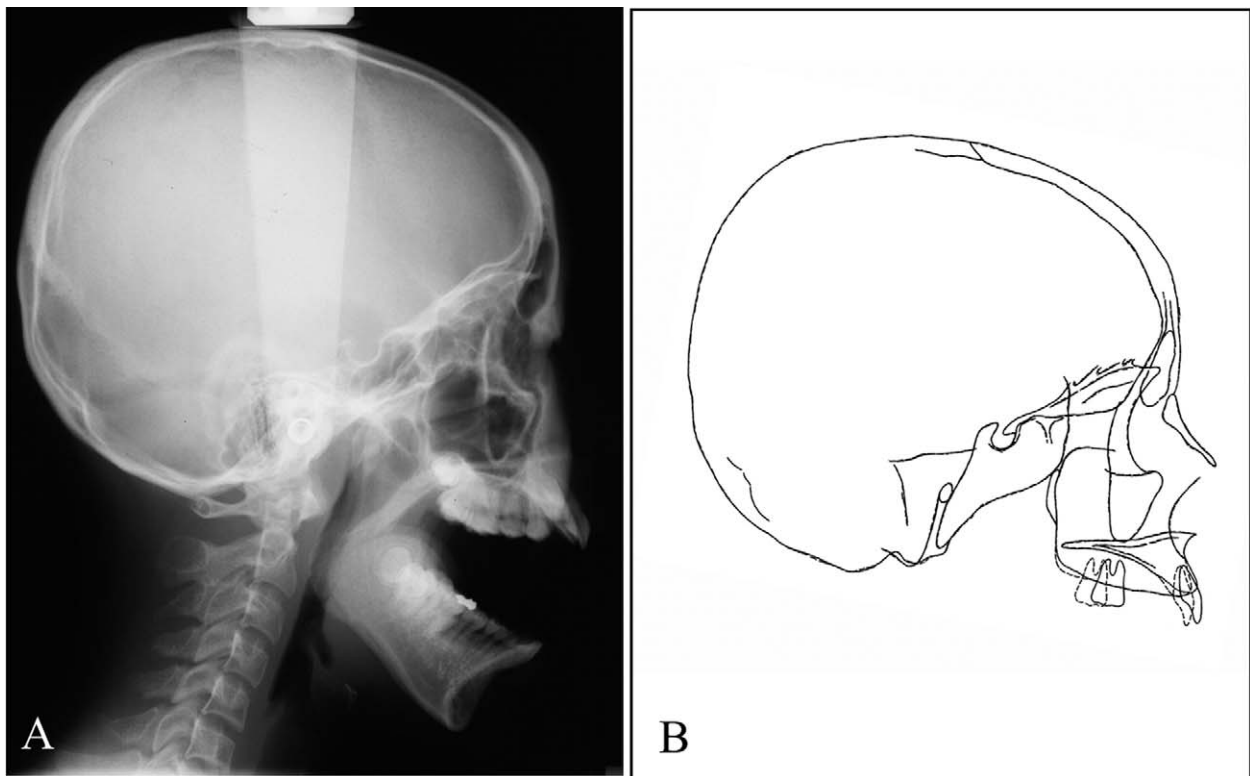
### RESULTS

Figure 5 is a scattergram of distal movement of the maxillary first-molar crowns and roots of all subjects. It shows the relationship between posterior displacement of the crowns and roots of the maxillary first molars individually. The average amounts of distalization at the crown and the root levels were 3.78 and 3.20 mm, respectively. The maximum crown displacement was 6.8 mm, and the minimum was 1.5 mm. The maximum root distalization was 6.0 mm, and the minimum was 1.3 mm. The correlation coefficient between crown and root distalization was 0.77, indicating that the crown and root movements were significantly correlated. The maxillary molar tended to show almost bodily translation with slight distal tipping.

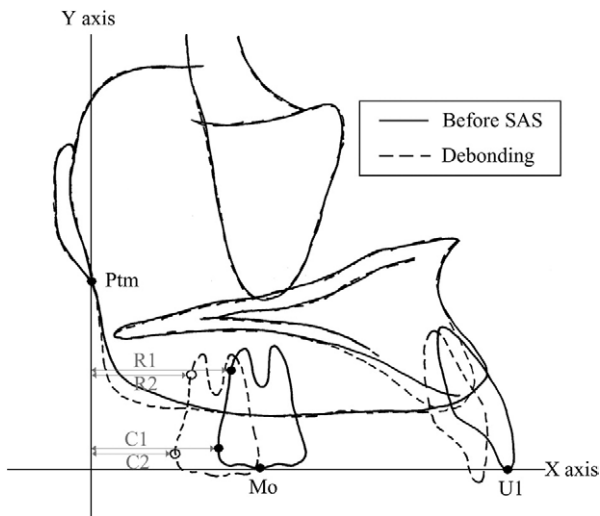
Distalization of the maxillary molars in all subjects was performed in accordance with individualized treatment goals established before the SAS treatment. Figure 6 shows the relationship between the treatment goals (C0) and the actual amount of distalization of the maxillary first-molar crowns. The correlation coefficient was 0.72, and it was statistically significant.

Figure 7 shows the relationships between the amount of distal movement of the maxillary first-molar crowns and the ages of the subjects. It also depicts the difference between the treatment goal and treatment





**Fig 3.** **A**, Roentgen cephalometric film in wide-opening; **B**, cephalometric superimposition before and after SAS treatment.



**Fig 4.** Planes and landmarks used for determining distal movement of maxillary first molar.

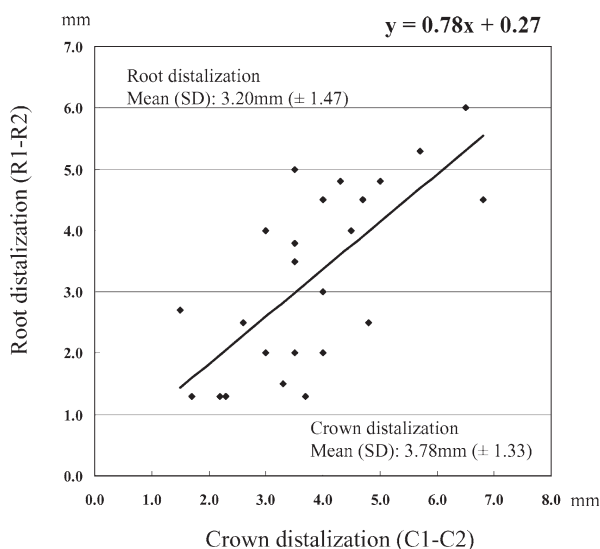
result in each subject. The extraction sites of posterior teeth are indicated with various symbols (Fig 7). The subjects were divided into 2 groups: those younger than 23 years 11 months and those older than 24 years. The

maxillary third molars were extracted in most subjects before SAS treatment, but all subjects whose second molars were extracted belonged to the younger group. All subjects without third molars belonged to the older group. There was no statistical difference in the amount of distal movement of the first molars between the younger and older groups. Regardless of variations in age and extraction site, the maxillary first molar could be distalized in accordance with individualized treatment goals with the SAS.

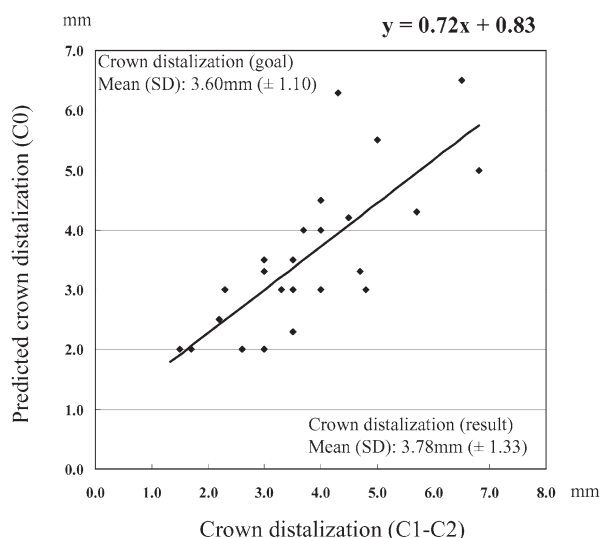
#### Case reports

The general purposes of distalization of the maxillary molars were to correct crowding of the dentition, to improve protrusion of the anterior dentition, and to decompensate the incisors in presurgical orthodontic treatment for severe Class III cases. Three subjects (1 in each category), chosen from those in this study, are described.

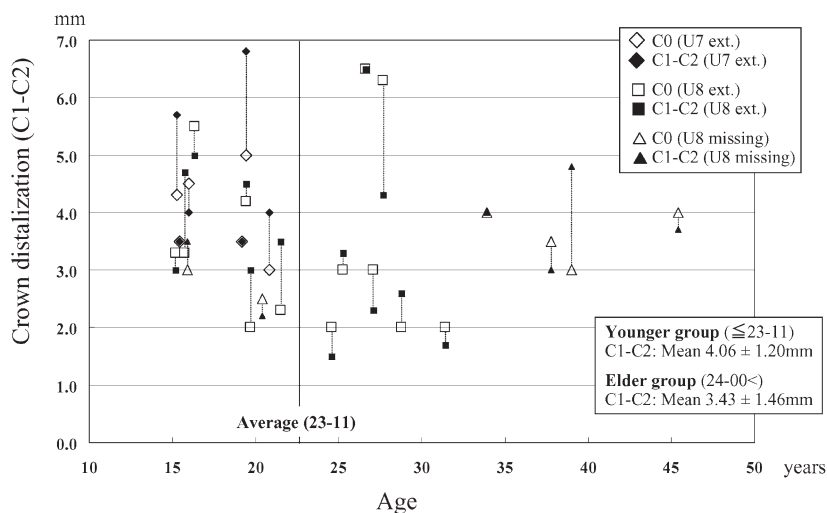
Subject 4 was seen initially at our clinic at age 8 for an anterior crossbite. After receiving the first phase of treatment with a maxillary protracting facial mask for 1.5 years, she remained under observation for growth-related changes. Immediately before the second phase



**Fig 5.** Crown-root distalization ratio of maxillary first molar. Because 2 subjects had same ratio (C1-C2, 3.0 mm; R1-R2, 2.0 mm), only 24 subjects are shown.



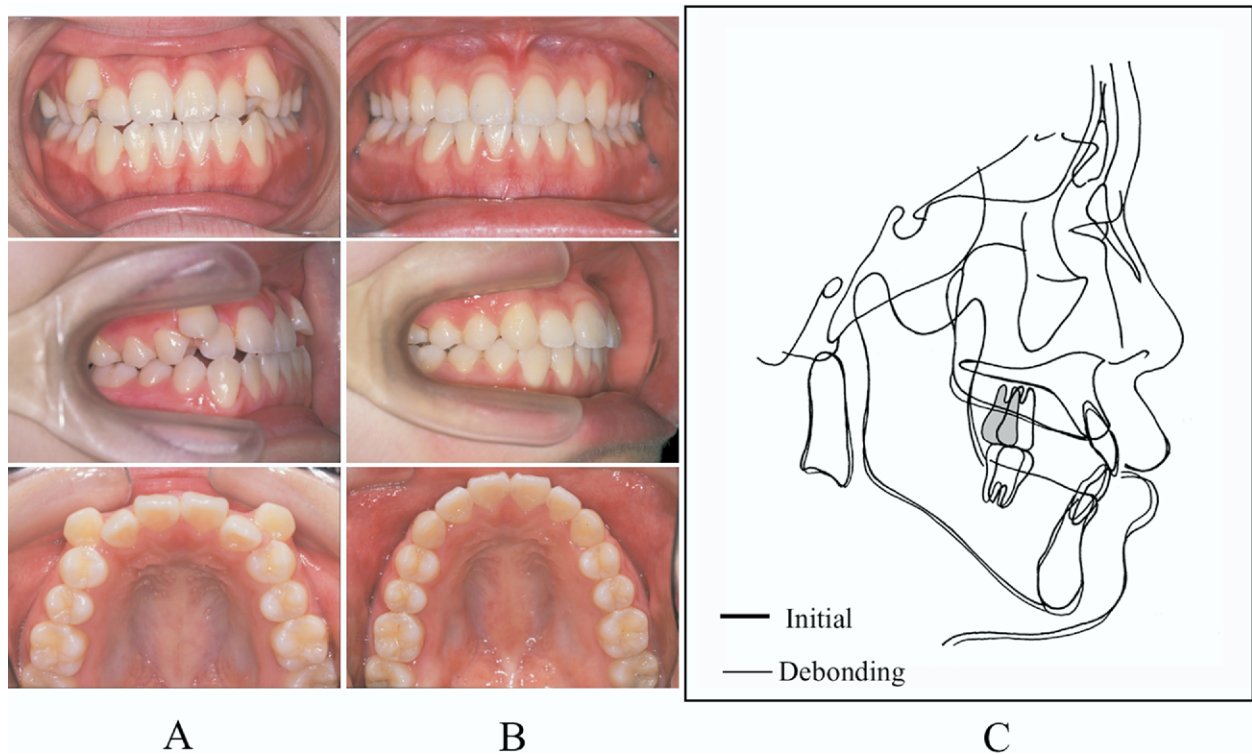
**Fig 6.** Difference between actual and predicted crown distalization of maxillary first molar. Because 2 subjects had same values (C0, 3.5 mm; C1-C2, 3.5 mm), only 24 subjects are shown.



**Fig 7.** Relationship among amount of crown distalization of maxillary first molar, patient's age, and difference from treatment goal. According to Student *t* test and Welch *t* test, *P* values were .24 and .26, respectively; therefore, there was no significant difference between younger and older groups.

of treatment (Fig 8, A), she had the following orthodontic problems: skeletal Class III tendency, severe crowding in the maxillary dentition, an edge-to-edge bite, a lack of anterior guidance, and Class III dentition. To solve those problems, Y-shaped and L-shaped anchor plates were bilaterally implanted at the zygomatic buttresses and the mandibular body, respectively, after extracting all third molars. SAS mechanics were applied to move the maxillary and mandibular molars

distally. After SAS treatment for approximately 13 months, the brackets were debonded (Fig 8, B), and a wraparound type of retainer for the maxillary dentition and a lingual bonded retainer in the mandibular anterior dentition were used. The severe crowding in the maxillary dentition was completely corrected by using SAS with no outward flaring of the maxillary incisors (Fig 8, C). The maxillary first molars were distalized in the manner of bodily translation. The amounts of posterior



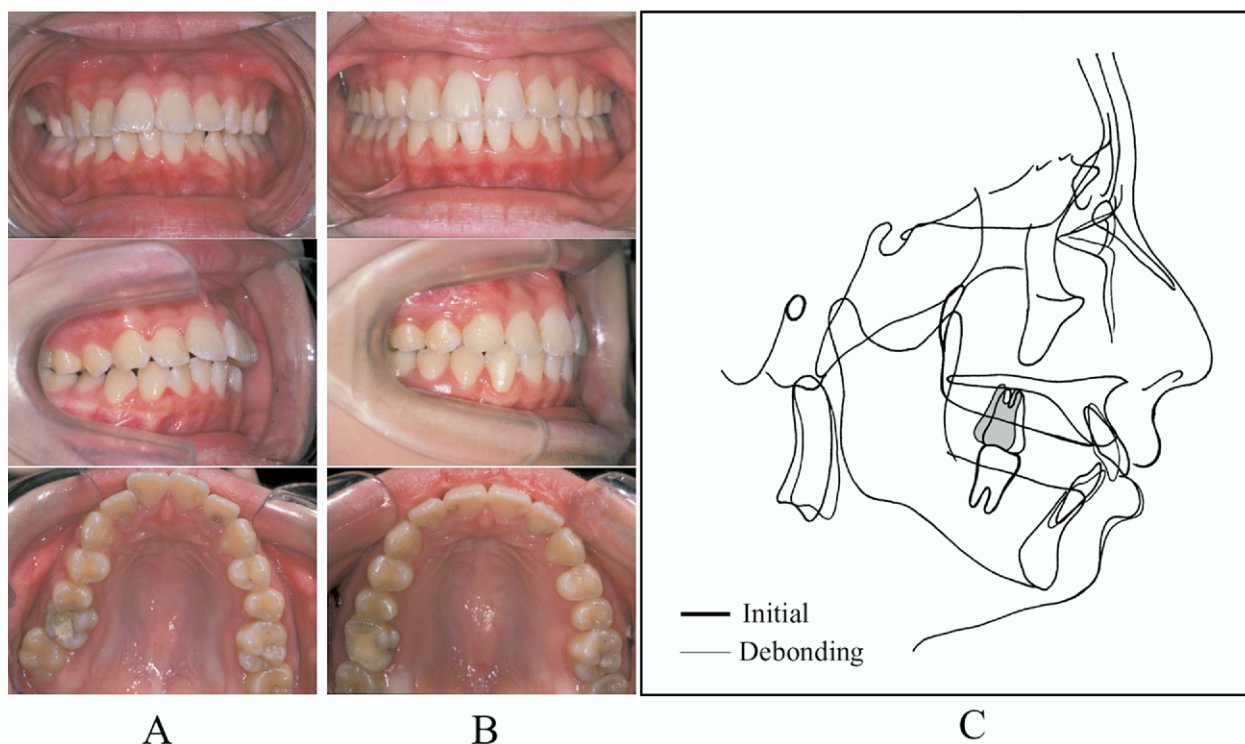
**Fig 8.** SAS treatment for crowding correction (subject 4): **A**, initial; **B**, debonding; **C**, cephalometric superimposition.

displacement of the crown and root were 4.7 and 4.5 mm, respectively. The mandibular first molars were also distalized and uprighted with SAS.<sup>39</sup> This patient might have had 4-premolar extractions in a traditional orthodontic diagnosis, but it became possible to treat her without extractions with the SAS.

Subject 1 was first seen at our clinic at age 15 with a Class II malocclusion and an unstable jaw position. Her orthodontic problems were skeletal Class II jaw relationship, small mandible, protrusion of the maxillary dentition, mandibular anterior crowding, crown collapse of the maxillary right first molar, and centric occlusion-centric relation difference (Fig 9, A). To camouflage her skeletal problems and solve the other dental problems, she chose SAS treatment. After extraction of all third molars, brackets were bonded, and the anchor plates were bilaterally placed at the zygomatic buttresses. Then the maxillary molars and the remaining maxillary teeth were distalized by using the SAS. Simultaneously, the mandibular posterior segments were uprighted with Class III elastics with anchor plates to prevent excessive flaring of the mandibular incisors. Figure 9, B, shows photos from immediately after debonding. The total treatment period was 29 months. Most of the orthodontic problems were

significantly improved with the SAS. She achieved stable functional occlusion after correction of the centric occlusion-centric relation difference. Eventually, her maxillary first molars were distalized 3.0 mm at the crown level and 2.0 mm at the root level (Fig 9, C). The predicted amount of crown displacement was 3.3 mm; therefore, it was almost coincident with the result. It is possible to predictably correct nongrowing Class II malocclusions without extracting premolars and without uncomfortable headgear.

Subject 20 was initially seen at our clinic at age 28 for his prognathic profile and total crossbite. The following problems were apparent at this examination: severe skeletal Class III jaw relationship, mandibular excess, lingual inclination of the mandibular incisors, labial inclination of the maxillary incisors, crowding of the maxillary dentition, minor mandibular incisor crowding, and severe Class III dentition (Fig 10, A). Mandibular setback osteotomy was chosen to solve his skeletal problems. Additionally, to correct the crowding of the maxillary dentition and to decompensate the maxillary incisors without premolar extractions, the SAS was used for presurgical orthodontic treatment. Figure 10, B, includes photos immediately after debonding. After undergoing SAS therapy, sagittal split



**Fig 9.** SAS treatment for Class II correction (subject 1): **A**, initial; **B**, debonding; **C**, cephalometric superimposition.

ramus osteotomy (SSRO) and genioplasty, his skeletal and dental problems were significantly improved (Fig 10, C). His maxillary first molars were moved distally 2.6 mm at the crown level and 2.5 mm at the root level. Previously, maxillary premolars were frequently extracted to decompensate the maxillary incisors in Class III surgical patients, but, since the development of the SAS, we rarely extract the premolars in presurgical orthodontics.

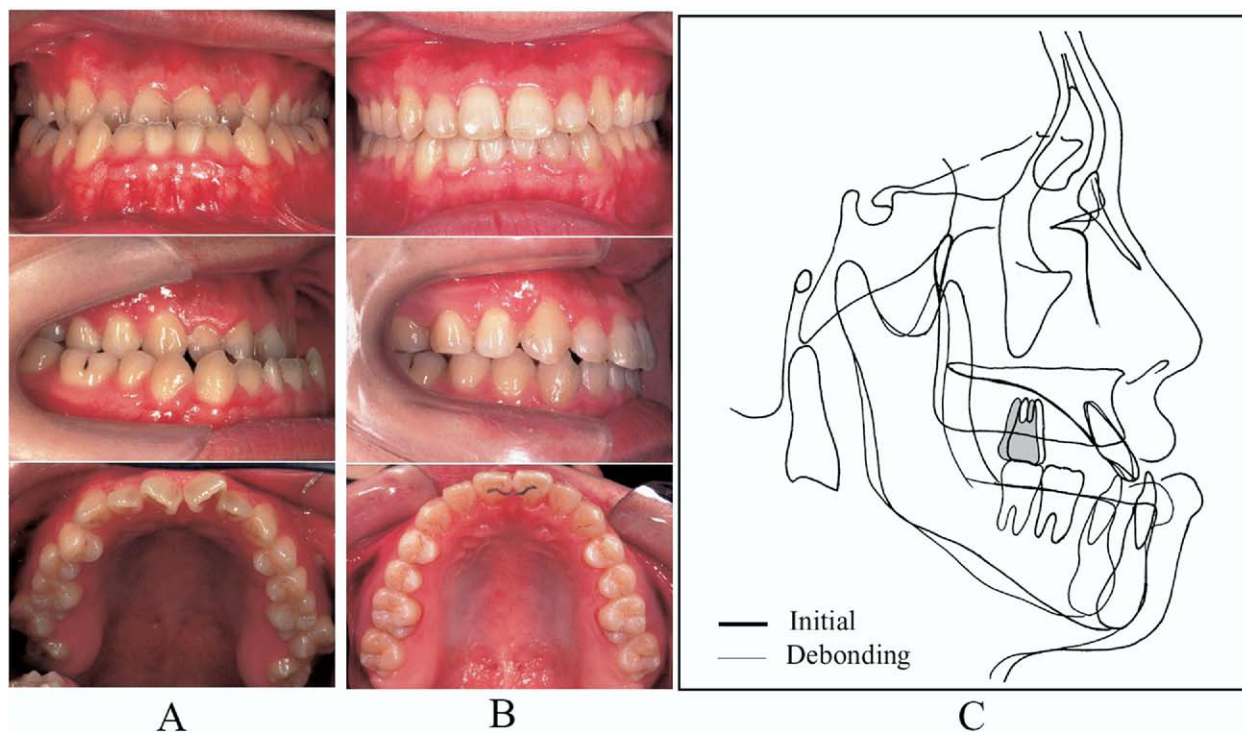
## DISCUSSION

The indications for intraoral distalizing appliances that have been previously reported were mostly Class II malocclusions. But the indications for distal movement with the SAS include not only Class II malocclusions but also any malocclusions characterized by crowding of the maxillary dentition and labial inclination of the maxillary incisors in any facial types, because the SAS enables simultaneous 3-dimensional control of the maxillary and mandibular molars.<sup>38-42</sup> Open-bite was a contraindication for previous intraoral distalizing appliances because of the increased lower facial height after distalization of the maxillary molars. In contrast, these might be indications for SAS treatment.<sup>40,41</sup> Actually, 10 of the 25 subjects in our study were open-bite

patients. Additionally, Class III surgical patients who required decompensation of the maxillary incisors in presurgical orthodontics are also candidates for distalization of the maxillary molars with the SAS.

The principal candidates for the previously reported intraoral distalizing appliances<sup>4-35</sup> were adolescent growing patients, because the distal movement of the first molars was thought to be easier to achieve before the eruption of the second molars.<sup>23</sup> But such an approach occasionally resulted in posterior crowding, eventually inducing a disturbance in the establishment of posterior support at the second molars, ectopic eruption of the third molars, and root resorption of the second molars after the eruption of the third molars. Therefore, the SAS has been used in nongrowing patients, taking into consideration the correspondence to the third molars. Usually, it is recommended to extract the third molars before distalization of the first molars with the SAS. But for patients whose second molars have serious problems—eg, dental caries, or endodontic and prosthetic problems, or if it would be difficult to extract the third molars—the second molars are extracted rather than the third molars. In this study, the second molars were extracted in 6 subjects under age 21. In addition, although the ages of the subjects in





**Fig 10.** SAS treatment for decompensation in Class III surgical case (subject 20): **A**, initial; **B**, debonding; **C**, cephalometric superimposition.

this study varied from 15 to 45 years, individualized treatment goals were achieved in most of them regardless of the age and extraction sites of the posterior teeth. Therefore, the maxillary molar distalizing mechanics with the SAS can be used for a wide range of ages, including adults.

A 2-stage method was commonly used to distalize maxillary molars with intraoral distalizing appliances as previously reported. The first molars were moved distally at the first stage. But anchorage loss—mesial movement of the premolars and labial tipping of the incisors—generally occurred as negative effects during molar distalization at this stage, even though the anchorage support comprised the second premolars, the Nance button, and a multi-bracketed appliance. Then, at the second stage, the premolars, the canines, and the incisors were retracted in sequence after reinforcing the anchorage of the molars that were distalized at the first stage.

It is important to address the amount of distalization of the maxillary first molars and anchorage loss at the first stage. But a more important matter is the anchorage slip of the distalized molars at the second stage. Unfortunately, this problem has not been seriously discussed in the previous reports. The progress of the maxillary molar distalization with the SAS is com-

pletely different from previous molar distalizing methods. The distalized molars are never required as part of the anchorage during retraction of the premolars and the anterior teeth, because the orthodontic force can be directly provided from the orthodontic anchor plates placed at the zygomatic buttresses. Accordingly, by using SAS treatment, it is possible to perform en-masse movement of the molars, the premolars, and the anterior dentition in sequence without a separation into 2 stages. The sequential and efficient distalization is a distinct advantage of SAS biomechanics as compared with previous methods.

Regarding the amount of the maxillary first-molar distalization, previous studies reported such results as 4.2 mm with repelling magnets,<sup>10</sup> 2.16 mm with the Wilson rapid molar distalizer,<sup>13</sup> 2.2 mm with repelling magnets,<sup>14</sup> 3.2 mm with the nickel-titanium coil spring,<sup>14</sup> 2.78 mm with a sectional jig assembly,<sup>24</sup> 4.8 mm with a distal jet,<sup>28</sup> 5.23 mm with an intraoral bodily molar distalizer,<sup>29</sup> 2.51 mm with a Jones jig,<sup>30</sup> and 5.7 mm with a pendulum appliance.<sup>29</sup> Most of these studies were conducted at the first stage for adolescent patients; the authors seldom evaluated the true amount of molar distalization after retraction of the premolars and the anterior teeth. Only Ngantung et al<sup>33</sup> reported that the maxillary first molar showed average mesial movement

of 3.9 mm after the second stage. This study suggested that it might be difficult to maintain the amount of molar distalization obtained at the first stage until the end of the second stage.

On the other hand, the amount of the maxillary first-molar distalization (3.78 mm) at the crown level described in our study is the value after the second stage. Therefore, the SAS can be considered an effective modality for noncompliance molar distalization. In addition, because the amount of the molar distalization at the root level was 3.20 mm on average, distalization with the SAS can be considered to represent almost bodily translation. To date, distal tipping of the molars has been described as a negative effect in molar distalization. It was also difficult to prevent distal tipping completely in SAS treatment, but it was not as difficult to correct the distal tipping of the molars during the multi-bracketed treatment by providing a compensating curve in the archwire or putting elastics up and down at the molar region.

Although goal-oriented strategies have been essential in recent orthodontics,<sup>43</sup> no previous report has mentioned treatment goals for distalization of the maxillary molars. In our study, the individualized treatment goals for distalization of the molars, incisor positions, and soft-tissue profiles were established with cephalometric and occlusogram predictions in all subjects before SAS treatment. Moreover, SAS treatment started after a double check on the 3-dimensional treatment goals by using setup models. Consequently, the predicted amount of maxillary first-molar crown distalization was 3.60 mm on average, and it was significantly correlated with the actual amount of distalization, 3.78 mm on average. It is therefore reasonable to suggest that the mechanics of SAS treatment for distalization of the maxillary molars is very predictable. It is a multifactorial problem to assess molar distalizing appliances, and it is not simply a matter of trying to distalize the molars as much as possible, but, rather, the achievement ratio of treatment goals should also be addressed.

## CONCLUSIONS

The SAS is a viable modality for distalizing maxillary molars because it uses stable and strong anchorage units. It enables not only single molar distalization but also en-masse movement of the maxillary buccal segments with only minor surgery for placing the titanium anchor plates at the zygomatic buttresses. Therefore, this new noncompliance technique is particularly useful for correcting Class II malocclusions, decompensation for Class III surgical patients, and malocclusions characterized by maxillary anterior

crowding. It rarely requires the extraction of the maxillary premolars.

## REFERENCES

1. Kloehn SJ. Evaluation of cervical traction of the maxilla and maxillary first permanent molar. *Angle Orthod* 1961;31:91-104.
2. Wieslander L. The effect of force on craniofacial development. *Am J Orthod* 1974;65:531-8.
3. Baumrind S, Korn EL, Isaacson RJ, West EE, Molthen R. Quantitative analysis of the orthodontic and orthopedic effects of maxillary traction. *Am J Orthod* 1983;84:384-93.
4. Cetlin NM, Ten Hoeve A. Nonextraction treatment. *J Clin Orthod* 1983;17:396-403.
5. Gianelly AA, Vaitas AS, Thomas WM, Berger DG. The use of magnets to move molars distally. *Am J Orthod Dentofacial Orthop* 1989;96:161-7.
6. Itoh T, Tokuda T, Kiyosue S, Hirose T, Matsumoto M, Chaconas S. Molar distalisation with repelling magnets. *J Clin Orthod* 1991;25:611-7.
7. Jackel N, Rakosi T. Molar distalisation by intraoral force application. *Eur J Orthod* 1991;13:43-5.
8. Gianelly AA, Bednar J, Dietz VS. Japanese NiTi coils used to move molars distally. *Am J Orthod Dentofacial Orthop* 1991;99:564-6.
9. Jones RD, White JM. Rapid Class II molar correction using an open coil jig. *J Clin Orthod* 1992;26:661-4.
10. Bondemark L, Kurol J. Distalization of maxillary first and second molars simultaneously with repelling magnets. *Eur J Orthod* 1992;14:264-72.
11. Hilgers JJ. The pendulum appliance for Class II non-compliance therapy. *J Clin Orthod* 1992;26:706-14.
12. Locatelli R, Bednar J, Dietz VS, Gianelly AA. Molar distalization with superelastic NiTi wire. *J Clin Orthod* 1992;26:277-9.
13. Muse DS, Fillman MJ, Emmerson WJ, Mitchell RD. Molar and incisor changes with Wilson rapid molar distalization. *Am J Orthod Dentofacial Orthop* 1993;104:556-65.
14. Bondemark L, Kurol J, Bernhold M. Repelling magnets versus superelastic NiTi simultaneous distal movement of maxillary first and second molars. *Angle Orthod* 1994;64:189-98.
15. Steger ER, Blechman AM. Case reports: molar distalization with static repelling magnets. Part II. *Am J Orthod Dentofacial Orthop* 1995;108:547-55.
16. Carano A, Testa M. The distal jet for upper molar distalization. *J Clin Orthod* 1996;30:374-80.
17. Ghosh J, Nanda RS. Evaluation of an intraoral maxillary molar distalization technique. *Am J Orthod Dentofacial Orthop* 1996;110:639-46.
18. Basdra EK, Huber H, Komposch G. A clinical report for distalizing maxillary molars by using super-elastic wires. *J Orofac Orthop* 1996;57:118-23.
19. Byloff FK, Darendeliler MA. Distal molar movement using the pendulum appliance, part 1: clinical and radiological evaluation. *Angle Orthod* 1997;67:249-60.
20. Byloff FK, Darendeliler MA, Clar E, Darendeliler A. Distal molar movement using the pendulum appliance, part 2: the effects of maxillary molar root uprighting bends. *Angle Orthod* 1997;67:261-70.
21. Erverdi N, Koyuturk O, Kucukkeles N. Nickel-titanium coil springs and repelling magnets—a comparison of two different intra-molar distalization techniques. *Br J Orthod* 1997;24:47-53.
22. Pieringer M, Droschl H, Permann R. Distalisation with a Nance appliance and coil spring. *J Clin Orthod* 1997;31:321-6.

23. Gianelly AA. Distal movement of maxillary molars. *Am J Orthod Dentofacial Orthop* 1998;114:66-72.
24. Gulati S, Kharbanda OP, Parkash H. Dental and skeletal changes after intraoral molar distalization with sectional jig assembly. *Am J Orthod Dentofacial Orthop* 1998;114:319-27.
25. Bondemark L, Kurol J. Class II correction with magnets and superelastic coils followed by straight-wire mechanotherapy. *J Orofac Orthop* 1998;59:127-38.
26. Runge ME, Martin JT, Bukai F. Analysis of rapid maxillary molar distal movement without patient cooperation. *Am J Orthod Dentofacial Orthop* 1999;115:153-7.
27. Scuzzo G, Pisani F, Takemoto K. Maxillary molar distalization with a modified pendulum appliance. *J Clin Orthod* 1999;33:645-50.
28. Fortini A, Lupoli M, Parri M. The first class appliance for rapid molar distalization. *J Clin Orthod* 1999;33:322-8.
29. Bussick T, McNamara JA Jr. Dentoalveolar and skeletal changes associated with the pendulum appliance. *Am J Orthod Dentofacial Orthop* 2000;117:333-43.
30. Brickman CD, Sinha PK, Nanda RS. Evaluation of the Jones jig appliance for distal molar movement. *Am J Orthod Dentofacial Orthop* 2000;118:526-34.
31. Keles A, Sayinsu K. A new approach in maxillary molar distalization: intraoral bodily molar distalizer. *Am J Orthod Dentofacial Orthop* 2000;117:39-48.
32. Quick AN, Harris AMP. Molar distalization with a modified distal jet appliance. *J Clin Orthod* 2000;34:419-23.
33. Ngantung V, Nanda RS, Bowman SJ. Posttreatment evaluation of the distal jet appliance. *Am J Orthod Dentofacial Orthop* 2001;120:178-85.
34. Champagne M. The NiTi distalizer: a non-compliance maxillary molar distalizer. *Int J Orthod Milwaukee* 2002;13:21-4.
35. Keles A, Pamukcu B, Tokmak EC. Bilateral maxillary molar distalization with sliding mechanics: Keles slider. *World J Orthod* 2002;3:57-66.
36. Wehrbein H, Glatzmaier J, Mundwiler U, Diedrich P. The orthosystem: a new implant system for orthodontic anchorage in the palate. *J Orofac Orthop* 1996;57:142-53.
37. Keles A, Erverdi N, Sezen S. Bodily distalization of molars with absolute anchorage. *Angle Orthod* 2003;73:471-82.
38. Sugawara J. Dr. Junji Sugawara on the skeletal anchorage system. *J Clin Orthod* 1999;33:689-96.
39. Sugawara J, Nishimura M. Minibone plates: the skeletal anchorage system. *Semin Orthod* 2005;11:47-56.
40. Umemori M, Sugawara J, Mitani H, Nagasaka H, Kawamura H. Skeletal anchorage system for open-bite correction. *Am J Orthod Dentofacial Orthop* 1999;115:166-74.
41. Sugawara J, Baik UB, Umemori M, Takahashi I, Nagasaka H, Kawamura H, et al. Treatment and posttreatment dentoalveolar changes following intrusion of mandibular molars with application of a skeletal anchorage system (SAS) for open bite correction. *Int J Adult Orthod Orthognath Surg* 2002;17:243-53.
42. Sugawara J, Daimaruya T, Umemori M, Nagasaka H, Takahashi I, Kawamura H, et al. Distal movement of mandibular molars in adult patients with the skeletal anchorage system. *Am J Orthod Dentofacial Orthop* 2004;125:130-8.
43. Burstone CJ, Marcotte MR. *Problem solving in orthodontics*. Chicago: Quintessence; 2000.

#### AVAILABILITY OF JOURNAL BACK ISSUES

As a service to our subscribers, copies of back issues of the *American Journal of Orthodontics and Dentofacial Orthopedics* for the preceding 5 years are maintained and are available for purchase from Mosby until inventory is depleted. Please write to Elsevier Inc. Subscription Customer Service, 6277 Sea Harbor Dr, Orlando, FL 32887, or call 800-654-2452 or 407-345-4000 for information on availability of particular issues and prices.